

Case Report

Occipital Nerve Stimulation with the Bion® Microstimulator for the Treatment of Medically Refractory Chronic Cluster Headache

Natalie H. Strand MD¹, Terrence L. Trentman MD², Bert B. Vargas MD³,
and David W. Dodick MD³

From: ¹Newport Beach Headache and Pain and ²Departments of Anesthesiology and ³Neurology, Mayo Clinic, Phoenix, AZ.

Dr. Strand is with the Newport Beach Headache and Pain Clinic.

Dr. Trentman is with the Department of Anesthesiology, Mayo Clinic, Scottsdale, AZ. Dr. Vargas and Dr. Dodick are with the Department of Neurology, Mayo Clinic Scottsdale, AZ.

Address correspondence:
Terrence L. Trentman, MD
Department of Anesthesiology
5777 East Mayo Blvd
Phoenix, AZ 85054
E-mail:
trentman.terrence@mayo.edu

Full disclosures page 440

Manuscript received: 05/07/2011
Accepted for publication: 08/15/2011

Free full manuscript:
www.painphysicianjournal.com

Background: Chronic cluster headache is a severely disabling neurological disorder. Evidence from open-label case series suggest that occipital nerve stimulation may be effective for the treatment of chronic cluster headache.

Objective: To evaluate the effectiveness of a microstimulator for chronic cluster headache.

Study Design: Prospective, observational feasibility study plus medical record review.

Settings: Academic medical center.

Methods: Four patients with medically refractory chronic cluster headache underwent implantation of a unilateral bion microstimulator. In-person follow-up was conducted for 12 months after implantation, and a prospective follow-up chart review was carried out to assess long term outcome.

Results: Three of the participants returned their headache diaries for evaluation. The mean duration of chronic cluster headache was 14.3 years (range 3 to 29 years). Pain was predominantly or exclusively retroocular/periocular. One participant demonstrated a positive response (> 50% reduction in cluster headache frequency) at 3 months post-implant, while there were 2 responders at 6 months. At least one of the participants continued to show > 60% reduction in headache frequency at 12 months. A chart review showed that at 58-67 months post-implant, all 3 participants reported continued use and benefit from stimulation. No side-shift in attacks was noted in any participant. Adverse events were limited to 2 participants with neck pain and/or cramping with stimulation at high amplitudes; one required revision for a faulty battery.

Limitations: Small patient population without control group. Not blinded or randomized.

Conclusion: Unilateral occipital nerve stimulation, using a minimally invasive microstimulator, may be effective for the treatment of medically refractory chronic cluster headache. This benefit may occur immediately after implantation, remain sustained up to 5 years after implantation, and occur despite the anterior location of the pain. Prospective, randomized controlled trials of occipital nerve stimulation in chronic cluster headache should proceed.

Key words: chronic headache, bion, peripheral nerve stimulation, cluster headache, migraine, occipital

Pain Physician 2011; 14:435-440

Chronic cluster headache (CCH) is a disabling neurological disorder which is often refractory to medical therapy. Novel, effective and well tolerated therapies are desperately needed for this patient population. Neurostimulation techniques, including deep (hypothalamic) brain (1,2) and occipital nerve stimulation (ONS), (3-5) have been reported to be effective for CCH, though ONS is arguably a preferred treatment modality because the surgery required for implantation is less invasive and has a lower risk of serious neurological morbidity. Occipital nerve stimulation systems include subcutaneous leads (wires) that are inserted transversely at approximately the C1 level and tunneled extensions from the leads to an impulse generator (IPG) in the chest wall, low back, or abdomen. Lead migration is the most common complication of ONS, likely due to the leads and extensions traversing the highly mobile neck and thorax to a remote IPG. Lead migration, which occurs in up to 60% of patients, often requires repeat surgery thereby increasing the risk of surgical and medical complications.

The bion microstimulator (Boston Scientific Neuro-modulation Corporation, Valencia, CA) is a cylindrical, rechargeable, telemetrically programmable, self-contained, lithium ion battery-powered device. It includes an integrated electrode and battery that are encased in a device that measures 27.5 mm x 3.2 mm (Fig. 1). Recently, the bion microstimulator was reported to be effective in the treatment of hemicrania continua (6). In this study, at a median follow-up of 13.5 months, 4

of 6 participants reported a substantial (80–95%) improvement in pain intensity. The onset of the benefit of ONS was delayed by days to weeks, and headaches did not recur for a similar period when the device was switched off. The device (which does not require the use of wires or leads) has a lower risk of migration, and was well tolerated and easily inserted without significant morbidity.

Herein, we report the results of ONS with a bion microstimulator in 3 participants with medically refractory CCH. The change in cluster headache frequency was assessed at 3 months, 6 and 12 months post-implantation. Long-term benefit was assessed through chart review between 58-67 months post-implantation.

METHODS

The study was approved by the United States Food and Drug Administration (IDE G030225) and our institutional review board. Written informed consent was obtained from each participant. Inclusion criteria included age 18 years of age or older, 12 or more months of medication, refractory chronic cluster headache, willingness to maintain a headache diary, and current pain medication regimen during the study. Exclusion criteria included planned or current pregnancy, participation in a device or drug trial within the previous 30 days, and previous occipital region surgery.

We have previously described the implant technique and stimulation parameters in 9 participants with refractory headache disorders including CCH who participated in a feasibility study of the bion microstim-




Fig. 1. The bion microstimulator. Reprinted from *Pain Physician* 2009, Trentman et al. with permission from the American Society of Interventional Pain Physicians.

ulator (7). In addition, we have described autonomic features in the absence of pain in 2 of the bion microstimulator participants, including one with CCH (8). As described in our previous manuscript, the 9 participants met the inclusion and exclusion criteria and all agreed to participate. All participants in the bion microstimulator feasibility study were evaluated by a headache specialist who classified their headaches using the criteria of the International Classification of Headache Disorders (ICHD-II).

The current study provides more in-depth information regarding 3 CCH patients who participated in the bion microstimulator feasibility study. Chronic cluster headache patients with comorbid primary headache disorders such as chronic migraine, or who later met the criteria for hemicrania continua, were excluded from the present study. Data was gathered using a written headache diary and included cluster attack frequency at one-month, 3-month, 6-month, and 12-month intervals. A positive response to occipital nerve stimulation was defined as a greater than 50% reduction in cluster headache frequency. Long-term benefit was assessed via a chart review of the participants' most recent description of bion microstimulator use and outcome.

As previously described, the bion microstimulator implant was performed with the participants in the prone position under monitored anesthesia care (7). The device was positioned subcutaneously and transversely in the occipital region, with the cathode immediately adjacent to the greater occipital nerve (GON) (Fig. 2). Intraoperative stimulation testing was performed to verify stimulation of the GON as evidenced by paresthesia towards the vertex of the head, at least to the level of the top of the ear. All participants underwent unilateral implantation adjacent to the GON, ipsilateral to the location of headache.

RESULTS

Four participants with CCH underwent implantation of the bion microstimulator. There were 2 men and 2 women with an age range of 44 to 66 years. The mean duration of CCH prior to entry into the study was 14.3 years (range 3 to 29 years). The location of maximal pain in all participants was retro-orbital and/or periorbital. Three of the participants returned their headache diaries for evaluation, while one did not use the stimulator or submit a diary secondary to unrelated health complications during follow-up.

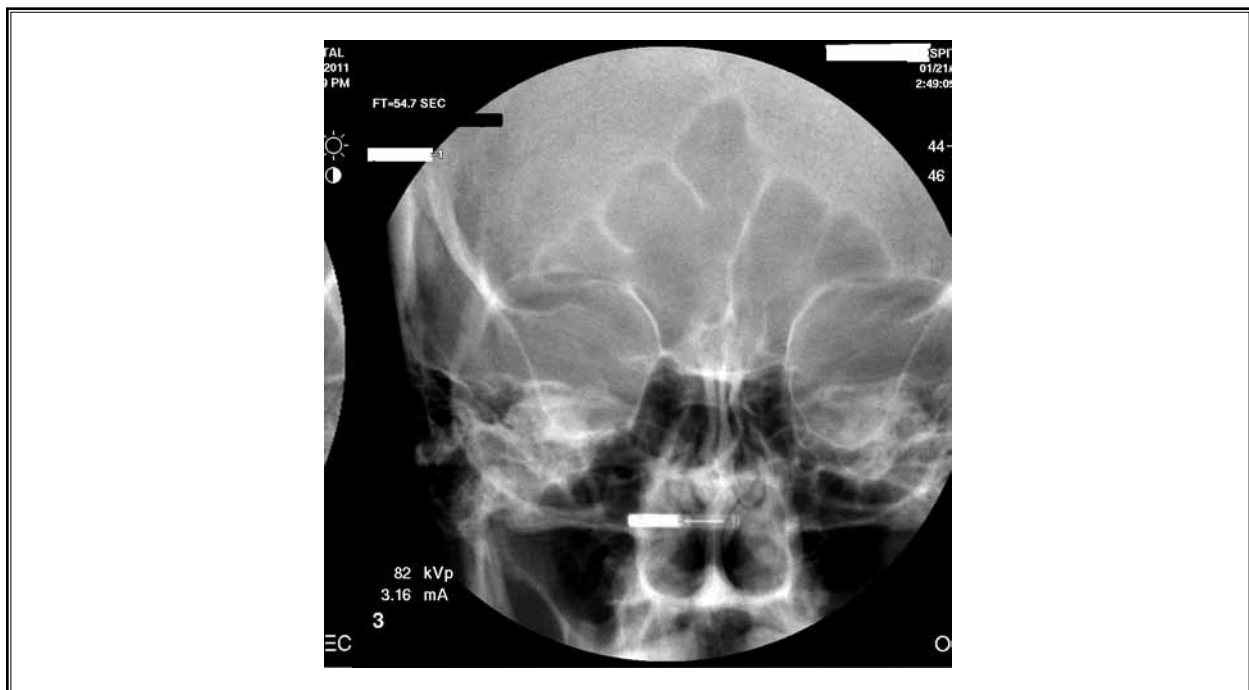


Fig. 2. *Bion microstimulator post-implantation.*

Participant 1 did not demonstrate a positive response (> 50% reduction in cluster headache frequency) until 6 months post-implant, but the benefit continued at 12-months. Participant 2 demonstrated a positive response only at one-month, but experienced a marked decrease in headache frequency throughout

the study period. Participant 3 demonstrated a positive response at each time interval but did not complete a 12 month diary. However, this participant verbally reported continued benefit at the 12-month mark that was comparable to the 3-month response (Figs. 3 and 4). As previously reported, adverse events were limited

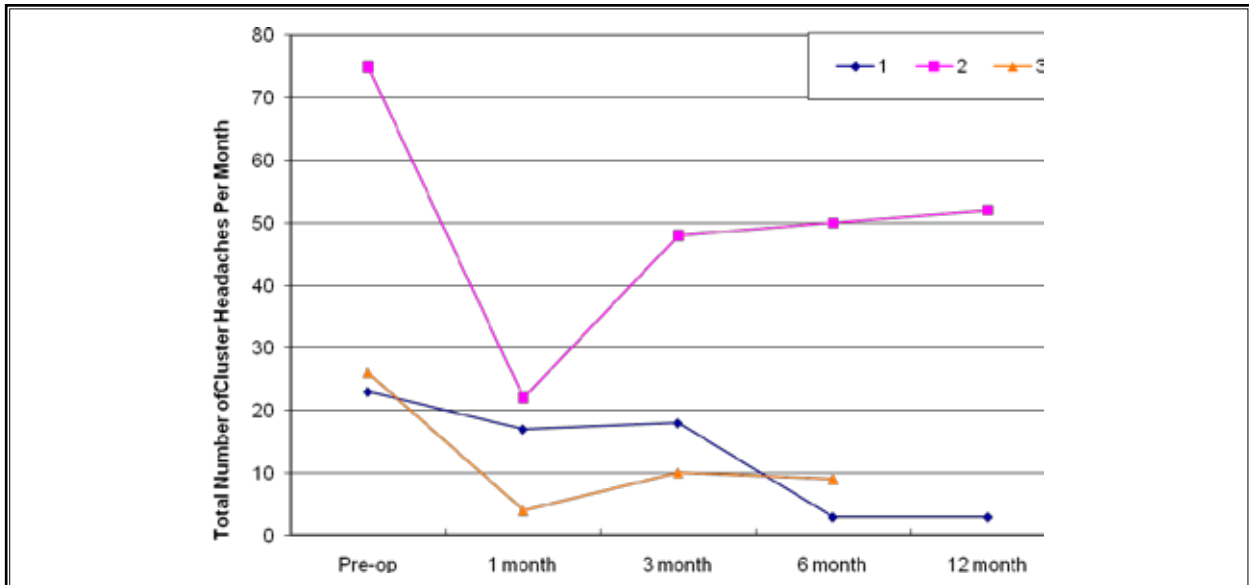


Fig. 3. Total number of cluster headaches per month during the study period.

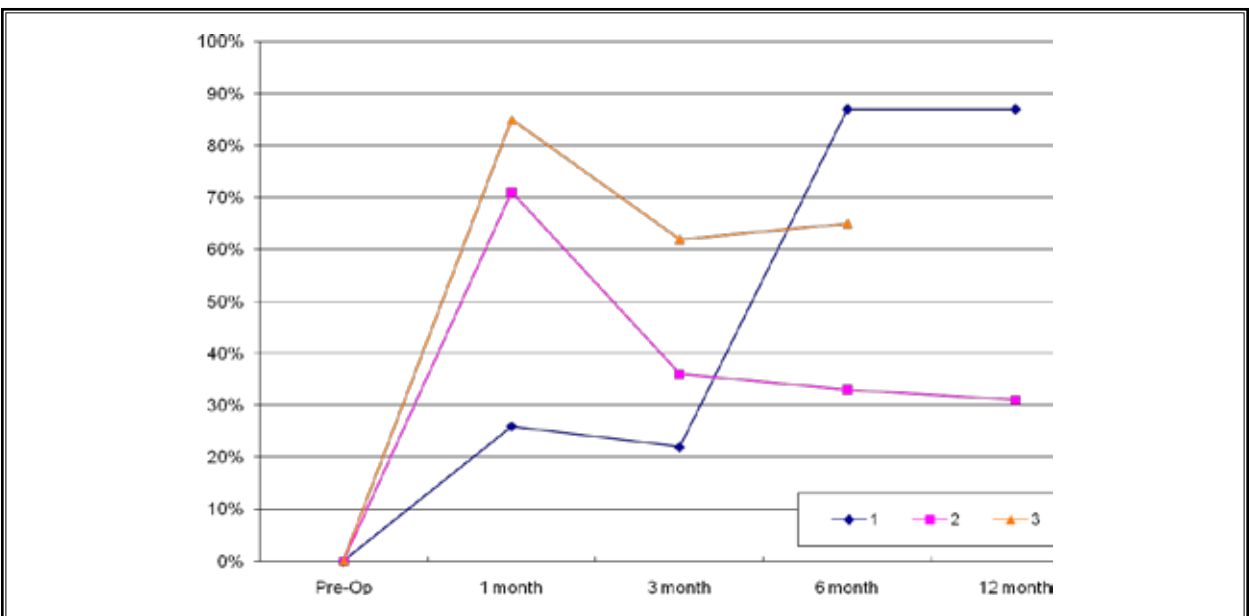


Fig. 4. Percent reduction in headache frequency.

to 2 participants who had neck pain and/or cramping with stimulation at high amplitudes and one participant who required revision for a faulty battery (7).

Regarding data obtained beyond the formal 12-month study period, we reviewed the medical records of each participant to find the most recent documentation of bion microstimulator use and outcome. This data was not part of the original study funded by Advanced Bionics Inc. (now Boston Scientific Neuro-modulation) and was collected solely by the authors, independent of the sponsored study.

Participant 1 was most recently contacted at 58 months post-implant. She reported continued bion microstimulator use and associated headache relief. Participant 2 reported continued use of the stimulator 67 months post-implant. He stated the bion microstimulator continued to help reduce his "less severe" cluster headaches, but he also required the use of abortive and prophylactic headache medications including verapamil, sumatriptan, prednisone, and dihydroergotamine. At 58 months post-implant, participant 3 reported "excellent" success with his bion microstimulator with continued use, and only 3 episodes of severe cluster headache since implantation.

Discussion

The results of this small feasibility study suggest that, for the first time, ONS using a microstimulator may have a role in the treatment of medically refractory CCH. One of 2 participants had a greater than 50% reduction in the frequency of headache at 3-months, and this degree of benefit was sustained in 2 of the participants at 12-months. Further, informal long-term follow-up of the participants suggested that the benefit of microstimulation for CCH continues for many years after implantation.

This study also demonstrated a number of other new and important findings. Over the course of one year, none of the participants experienced contralateral attacks of cluster headache, a phenomenon that has been previously recognized in CCH, even in those without a prior history of attacks alternating sides. In addition, this study demonstrated the potential for limiting stimulation only to the side ipsilateral to the attacks, thereby limiting the need for bilateral stimulation. Finally, despite the fact that the location of the pain was retro-orbital/periorbital, stimulation in the occipital nerve region has the potential to reduce the frequency and severity of attacks that occur predominantly or exclusively in the first division of the trigeminal nerve.

There was no evidence of device migration; however, one participant did require repeat surgery for a battery malfunction. The use of a wireless IPG may eliminate the common complication of lead migration associated with conventional ONS systems, by eliminating the mechanical stress placed on the leads associated with neck mobility(9). In addition, a wireless IPG does not require tunneling or remote implantation of a larger IPG, which makes the implantation significantly less invasive. This may lead to increased patient satisfaction and comfort.

Contrary to previous reports which appeared to indicate a delay from the time of implantation to clinical benefit of up to several months, (3,10) the results of this study indicate that the benefit of ONS was evident in each participant to variable degrees immediately after implantation. This is consistent with our clinical experience and with our previously published experience using ONS for a variety of primary headache disorders(9). Additionally, the benefit appeared to accumulate and grow over time. This is an important observation, since ONS is a relatively invasive and costly procedure. Therefore, a trial period of stimulation prior to permanent implantation is recommended by our team, since a positive or negative response may be predictive of long-term outcome and avoid the cost and morbidity associated with permanent implantation in those who are very unlikely to respond.

The limitations of this analysis are several. Obviously, this study was not sham-controlled and the participants were unblinded to treatment. One may hypothesize, however, that the placebo response rate in these participants would be expected to be low, given the average duration of CCH was 14.3 years, and all of them failed countless trials of medications and other treatment strategies. Furthermore, as shown by data collected by the authors beyond the original 12 month study, the positive response and continued reliance on the stimulator persisted up to 67 months after implantation. Therefore, we believe these results, combined with those open studies using conventional ONS systems in participants with CCH, support the need for prospective, randomized, blinded, and controlled studies of ONS in CCH in general, and a study using a microstimulator in particular.

The number of participants in this study is too small to draw conclusions regarding the efficacy of traditional occipital nerve stimulators compared to the bion microstimulator in chronic cluster headache. However, a strength of this study was the use of a daily headache

diary with detailed information regarding total headaches per month. All of the participants who completed the 12-month study experienced a reduction in headache days, including 2 who had a sustained reduction of > 60%. In a previous study, 14 participants with CCH evaluated the use of bilateral occipital nerve stimulators over an average time of 17.5 months (11). Ten out of 14 reported improvement, with 3 reporting a marked improvement of 90% or better; 3 reporting a moderate improvement of 40% or better; and 4 reporting a mild improvement of 20-30% (improvement was measured by the participants' estimate of percent change).

Magis et al (12) performed a study evaluating 8 participants with CCH and found a mean reduction of 79.9% in frequency of attacks in those implanted with a lead on the ipsilateral side to their headache. These results are somewhat larger, yet comparable, to the reduction in CCH frequency observed with the bion microstimulator.

The results of this study support the previously observed potential efficacy of ONS for medically refractory CCH. It also suggests that the bion microstimulator is as effective as traditional wire leads. This study also extends previous observations from the bion microstimulator feasibility study in providing outcome data for the past 5 years. The most common adverse event with occipital nerve stimulation is lead migration, with up to

100% of patients needing revision for lead migration within three years (9). It is possible that the wireless components of the bion microstimulator decrease the likelihood of lead migration, thus minimizing morbidity and long-term complications frequently associated with available technology.

DISCLOSURES

Conflicts of Interest: Within the past 2 years, Drs Trentman, Dodick and Vargas have received research support from St Jude-Neuromodulation, Plano, TX and Medtronic Inc., Minneapolis, MN. Dr Dodick has provided consulting services within the past 2 years for Medtronic, Inc. and Boston Scientific Corporation, Natick, MA. In the remote past (> 3 years), Dr Trentman provided consulting services for Advanced Bionics Corporation, Valencia, CA.

Previous presentations: As noted in the manuscript, publications that include some or all of the patients described in the present work are in print (Trentman et al., *Pain Physician*, 2009; Schwedt et al. *Cephalalgia*, 2006). Also, an abstract based on this data was presented at the American Headache Society, Boston MA, Headache 2008 May; 48(Suppl 1):S52.

Funding: this study was supported by funding from Advanced Bionics® Corporation, now Boston Scientific Neuromodulation, Valencia, CA.

REFERENCES

- Sillay KA, Sani S, Starr PA. Deep brain stimulation for medically intractable cluster headache. *Neurobiol Dis* 2010; 38:361-368.
- Fontaine D, Lazorthes Y, Mertens P, Blond S, Geraud G, Fabre N, Navez M, Lucas C, Dubois F, Gonfrier S, Paquis P, Lanteri-Minet M. Safety and efficacy of deep brain stimulation in refractory cluster headache: A randomized placebo-controlled double-blind trial followed by a 1-year open extension. *J Headache Pain* 2010; 11:23-31.
- Burns B, Watkins L, Goadsby PJ. Treatment of medically intractable cluster headache by occipital nerve stimulation: Long-term follow-up of eight patients. *Lancet* 2007; 369:1099-1106.
- Mueller OM, Gaul C, Katsarava Z, Diener HC, Sure U, Gasser T. Occipital nerve stimulation for the treatment of chronic cluster headache - lessons learned from 18 months experience. *Cen Eur Neurosurg* 2011; 72:84-89.
- Muller OM, Gaul C, Katsarava Z, Sure U, Diener HC, Gasser T. [Bilateral occipital nerve stimulation for the treatment of chronic cluster headache: case series and initiation of a prospective study]. *Fortschr Neurol Psychiatr* 2010; 78:709-714.
- Burns B, Watkins L, Goadsby PJ. Treatment of hemicrania continua by occipital nerve stimulation with a bion device: Long-term follow-up of a crossover study. *Lancet Neurol* 2008; 7:1001-1012.
- Trentman TL, Rosenfeld DM, Vargas BB, Schwedt TJ, Zimmerman RS, Dodick DW. Greater occipital nerve stimulation via the Bion microstimulator: Implantation technique and stimulation parameters. Clinical trial: NCT00205894. *Pain Physician* 2009; 12:621-628.
- Schwedt TJ, Dodick DW, Trentman TL, Zimmerman RS. Occipital nerve stimulation for chronic cluster headache and hemicrania continua: Pain relief and persistence of autonomic features. *Cephalalgia* 2006; 26:1025-1027.
- Schwedt TJ, Dodick DW, Hentz J, Trentman TL, Zimmerman RS. Occipital nerve stimulation for chronic headache-long-term safety and efficacy. *Cephalalgia* 2007; 27:153-157.
- Magis D, Allena M, Bolla M, De Pasqua V, Remacle JM, Schoenen J. Occipital nerve stimulation for drug-resistant chronic cluster headache: A prospective pilot study. *Lancet Neurol* 2007; 6:314-321.
- Burns B, Watkins L, Goadsby PJ. Treatment of intractable chronic cluster headache by occipital nerve stimulation in 14 patients. *Neurology* 2009; 72:341-345.
- Magis D, Schoenen J. Neurostimulation in chronic cluster headache. *Curr Pain Headache Rep* 2008; 12:145-153.