

Prospective Evaluation

## Occipital Nerve Stimulation in the Treatment of Medically Intractable SUNCT and SUNA

Giorgio Lambru MD<sup>1</sup>, Paul Shanahan MB, BCh, BAO, MRCP<sup>1</sup>,  
Laurence Watkins MD, FRCS,<sup>2</sup> and Manjit Singh Matharu, MBChB, MRCP, PhD<sup>1</sup>

From: <sup>1</sup>Headache Group and  
<sup>2</sup>Division of Neurosurgery;  
Institute of Neurology and The  
National Hospital for Neurology  
and Neurosurgery, Queen  
Square, London, UK

Address Correspondence:  
Dr MS Matharu  
Senior Lecturer and Honorary  
Consultant Neurologist  
Headache Group, Institute of  
Neurology and The National  
Hospital for Neurology and  
Neurosurgery, Queen Square,  
London WC1N 3BG  
Email: m.matharu@uclmail.net

Disclaimer: There was no  
external funding in the  
preparation of this manuscript.  
Conflict of interest: Each author  
certifies that he or she, or a  
member of his or her immediate  
family, has no commercial  
association (i.e., consultancies,  
stock ownership, equity interest,  
patent/licensing arrangements,  
etc.) that might pose a conflict of  
interest in connection with the  
submitted manuscript.

Manuscript received: 06-03-2013  
Revised manuscript received:  
07-31-2013  
Accepted for publication:  
09-11-2013

Free full manuscript:  
[www.painphysicianjournal.com](http://www.painphysicianjournal.com)

**Background:** Short-lasting unilateral neuralgiform headache attacks with conjunctival injection and tearing (SUNCT) or with cranial autonomic symptoms (SUNA) are primary headaches characterized by frequent attacks of severe headaches in association with cranial autonomic features. Patients with chronic SUNCT or SUNA have unremitting symptoms that necessitate prolonged use of medical preventive treatments, many of which are prone to causing side effects. They can be medically intractable, in which case neurally destructive or cranially invasive surgical treatments can be offered, though these have hitherto yielded conflicting results. Occipital nerve stimulation (ONS) offers a nondestructive and relatively low risk surgical alternative.

**Objective:** To assess the efficacy and safety of ONS in chronic, medically intractable SUNCT and SUNA patients.

**Study design:** Prospective open-label study.

**Methods:** Nine medically intractable, chronic SUNCT and SUNA patients were implanted with electrodes for bilateral occipital nerve stimulation. Data were collected prospectively for pre- and postimplantation headache characteristics, including frequency, intensity and duration of attacks. Diaries were used to assess headache improvement.

**Results:** At a median follow-up of 38 months (range 24–55 months), all but one patient reported substantial improvement. Four patients became pain-free, 3 were almost pain-free (96 – 98% improvement), and one had a marked reduction in attack frequency and severity (81% improvement). After an initial rapid improvement, the maximum benefit of ONS was attained after a lag of a few months. Device malfunction was followed by recurrence or worsening of the attacks within a few days in most patients. Adverse events included lead migration, exposure of the electrode, and pain due to muscle recruitment over the leads. One patient developed hemicrania continua one month after implantation and was successfully treated with indomethacin.

**Conclusion:** ONS appears to offer an effective and safe treatment option, without significant morbidity, for medically intractable SUNCT and SUNA. Given the variable results with cranially invasive or neurally destructive surgery, ONS might be considered the surgical treatment of choice for medically intractable SUNCT and SUNA.

**Key words:** SUNCT, SUNA, occipital nerve stimulation, trigeminal autonomic cephalalgias, neuromodulation, peripheral nerve stimulation, trigeminal neuralgia, greater occipital nerve blockade

Pain Physician 2014; 17:29-41

**S**hort-lasting unilateral neuralgiform headache attacks with conjunctival injection and tearing (SUNCT) is a primary headache syndrome characterized by attacks of unilateral orbital,

supraorbital, or temporal stabbing or pulsating pain of moderate to severe intensity. Attacks occur with a frequency of 3 to 200 per day, last from 5 seconds to 4 minutes, and are accompanied by ipsilateral

conjunctival injection and lacrimation. In recognition of the possibility that all patients with generically the same condition might not have both conjunctival injection and tearing, the International Headache Society Classification Committee proposed that SUNCT may be a subset of short-lasting unilateral neuralgiform headache attacks with cranial autonomic symptoms (SUNA) (1). In SUNA there may be cranial autonomic symptoms other than conjunctival injection and lacrimation, or indeed only one of these symptoms may be present. SUNCT and SUNA can occur in episodic or chronic forms. The chronic form is defined as having a continuous remission period of no more than one month in every 12 months. Approximately 70% of patients have the chronic variant (2).

Lamotrigine is considered the drug of choice, while topiramate and gabapentin can also be effective (3,4). Furthermore SUNCT and SUNA seem to show an effective, but usually short-lasting response to intravenous lidocaine (3).

Some patients with chronic SUNCT and SUNA are refractory to medical treatments, although the extent of this problem is unknown. Several destructive or invasive approaches involving the trigeminal nerve have been reported in these patients (5-9). The effectiveness of these procedures is uncertain as the reported results are often conflicting and the follow-up period is generally very limited. These procedures are also known to be associated with various complications including corneal anesthesia, anesthesia dolorosa, jaw deviation, diplopia, and audiovestibular disturbance.

Neurostimulation therapies that entail peripheral or central nervous system targets are emerging as very promising approaches for the management of medically intractable headache disorders. Based upon the finding of posterior hypothalamic region activation in SUNCT (10,3), 3 medically intractable SUNCT patients have been treated with posterior hypothalamic deep brain stimulation (DBS) showing good preliminary results (11-13). This procedure is associated with a small risk of fatal hemorrhage(14).

Peripheral stimulation of the occipital nerve has been reported in various medically refractory primary headache disorders in open label studies with promising results (15-18). Recently, 2 randomized, multicenter, double-blinded, sham-controlled occipital nerve stimulation (ONS) studies in chronic migraine were published (19,20). The benefits shown in those trials were significantly less dramatic compared to the open label experience, failing to draw a definite conclusion about

the efficacy of this technique in this group of patients, especially because of the difficulty to create a reliable sham-group, since paresthesia is required to achieve a clinical response.

The experience of ONS in trigeminal autonomic cephalalgias (TACs) is limited to cluster headache (CH). Ninety-one cases of chronic, medically intractable CH treated with ONS have been reported in open label studies with encouraging results in terms of efficacy and safety (21).

On the basis of the evidence for efficacy and safety of ONS in various headache disorders, and our concerns about the safety of hypothalamic DBS taken together with the devastating morbidity of medically intractable SUNCT and SUNA, we began to offer ONS implantations to these patients. We report the systematic long-term follow-up of these patients.

## **METHODS**

---

### **Patients**

Patients with medically intractable, chronic SUNCT and SUNA under our care were offered an occipital nerve stimulator. The diagnosis of SUNCT was established according to International Classification of Headache Disorders II criteria, while the proposed appendix criteria were used for the diagnosis of SUNA (1).

All patients fulfilled the standard criteria, with the exception of one SUNA patient who had facial redness and sweating but none of the cranial autonomic features delineated in the standard criteria (Table 1). While all patients fulfilled the standard diagnostic criteria for duration of attacks, some patients also had longer lasting attacks which have been described in the largest clinical series of SUNCT and SUNA patients (2). All patients had a trial of oral indomethacin or a modified indo-test (100 or 200 mg of intramuscular indomethacin versus saline placebo) (22) to rule out indomethacin-responsive headaches. Patients with attacks lasting longer than 4 minutes also had trials of high flow oxygen and subcutaneous sumatriptan, which can be beneficial in cluster headache but are ineffective in SUNCT and SUNA.

Patients were considered suitable for ONS if they had highly disabling, medically intractable, chronic SUNCT or SUNA for at least 2 years. Unlike in cluster headache (23), medically intractable SUNCT/SUNA is not clearly defined in the literature. Patients were considered medically intractable if they failed to respond to adequate trials, at appropriate doses for an appropriate length of time, of lamotrigine, topiramate, gaba-

## Occipital Nerve Stimulation in the Treatment of SUNCT and SUNA

Table 1. *Clinical features and investigation results.*

|   | Diagnosis | Quality of Pain             | Side/Site of the Attacks | Duration of Attacks in Seconds (Range) | Cranial Autonomic Symptoms                                  | Frequency of Attacks/d (Range) | Triggered, Spontaneous, or Both Attacks | Refractory Period Following Attacks Triggered From Trigger Areas | MRI Scan Result   |
|---|-----------|-----------------------------|--------------------------|--|---|--------------------------------|---|--|---|
| 1 | SUNCT     | Stabbing, burning, sharp    | R/V1                     | 660 (120–900)                          | Conjunctival injection, lacrimation, rhinorrhea             | 46 (0–97)**                    | B                                       | No   | Right SCA in contact with the trigeminal nerve at the REZ. Minor age-related involutional changes.                                |
| 2 | SUNA      | Stabbing, sharp, pulsating  | L/V1                     | 240 (120–600)                          | Sweating and flushing of the face                           | 33 (8–52)                      | B                                       | No   | Incidental small pineal cyst.   |
| 3 | SUNCT     | Stabbing                    | R/V1                     | 32 (20–1920)                           | Ptosis, conjunctival injection, lacrimation, blocked nose   | 30 (16–40)                     | B                                       | No   | Normal.   |
| 4 | SUNCT     | Stabbing, jabbing, sharp    | L(R)/V1+ occipital       | 120 (60–360)                           | Conjunctival injection, lacrimation, swelling of the eyelid | 12 (3–20)                      | S                                       | No triggered attacks   | Normal.   |
| 5 | SUNCT     | Stabbing                    | L/V1–V2                  | 25 (5–75)                              | Conjunctival injection, lacrimation, ptosis, miosis         | 90 (48–150)                    | T                                       | No   | Several non-specific cerebral white matter lesions.   |
| 6 | SUNCT     | Stabbing, sharp             | R(L)/V1                  | 120 (60–600)                           | Conjunctival injection, lacrimation, eyelid edema           | 30 (6–103)                     | S                                       | No triggered attacks   | Bilateral arterial loops in contact with the trigeminal nerves at the REZ. Several non-specific subcortical white matter lesions. |
| 7 | SUNA      | Shooting, sharp             | R/V1–V2                  | 5 (1–1800)                             | Lacrimation, sweating and flushing of the face              | 20.5 (16–42)                   | B                                       | No   | Normal.   |
| 8 | SUNA      | Stabbing, sharp             | L(R)/V1+ occipital       | 120 (5–600)                            | Conjunctival injection                                      | 79 (5–154)                     | S                                       | No triggered attacks   | Right frontal cortical dysplasia.   |
| 9 | SUNCT     | Stabbing, shooting, burning | R/V1+ retro auricular    | 10 (5–1800)                            | Conjunctival injection, lacrimation, blocked nose           | 72 (18–96)                     | S                                       | No triggered attacks   | Normal.   |

B: both triggered and spontaneous attacks; F: female; L: left side; (L): Attacks can present occasionally on the left side; M: male; R: right side; (R): Attacks can present occasionally on the right side; REZ: root entry zone; S: Spontaneous attacks only; SCA: superior cerebellar artery; T: Attacks triggered from triggers zones; V1: Cutaneous territory innervated by the first division of the trigeminal nerve; V2: Cutaneous territory innervated by the second division of the trigeminal nerve; \*\*Patient 1 had a maximum of 3-5 pain free days /month

pentin, pregabalin, and one of either carbamazepine or oxcarbazepine. These agents were selected on the basis of the available evidence of the efficacy of these agents (3,4) and our experience. A failed trial was defined as an unsatisfactory response, development of intolerable side effects, or contraindication to the use of the agent.

A stimulation trial with external leads is performed for several days before the permanent implantation in some centers, with a view to improving the selection of candidates for permanent stimulation. This practice is not used at our unit and therefore it was not a selection criterion. Similarly, most patients had a greater

occipital nerve injection (GONI), with a mixture of 2 mL of 2% lidocaine and methylprednisolone 80 mg, but the response to the GONI was not a selection criterion.

The patients were given implants on compassionate grounds. The study was an audit of outcomes, and as such, it did not require ethics board approval under UK guidelines. All patients gave written informed consent.

### Surgical procedure

Bilateral ONS electrodes, leads, and battery were implanted after informed consent was obtained. The implant technique has evolved overtime in our center. In earlier SUNCT and SUNA cases, the insertion point was at the spinous process of C1, passing laterally and superiorly, using a Tuohy needle curved to follow the cervical fascia. However, in order to reduce possible complications such as unwanted stimulation of the neck muscles, which can limit the amplitude of stimulation that can be applied and erosion of the electrode tip through the skin, the implantation level in more recent cases has been aimed at stimulating the greater

occipital nerve as it emerges superior to the nuchal line. This means that the electrode is superior to the cervical muscles, thus reducing the chance of unwanted muscle stimulation. Since the electrode can be passed in the loose subgaleal plane at this level, we did not use a sharp insertion technique (Tuohy needle) but instead passed the electrodes using a blunt plastic tube, thus reducing the chance that the tip would be tunneled closer to the skin than intended, at the extreme lateral tip of the electrode. Figure 1 illustrates patients operated with the earlier technique, where electrodes originated from the level of the spinous process of C1 (Cases 1, 2, 4, 6) and those implanted using the later technique, with electrodes placed superior to the nuchal line (Cases 7 and 8). It is unlikely that this difference in the implant technique could account for a difference in therapeutic outcome since the target is still stimulation of the greater occipital nerve. The difference was only aimed to reduce ONS-related adverse events.

A single-stage procedure in 2 parts was used to allow an intraoperative stimulation trial. The first part

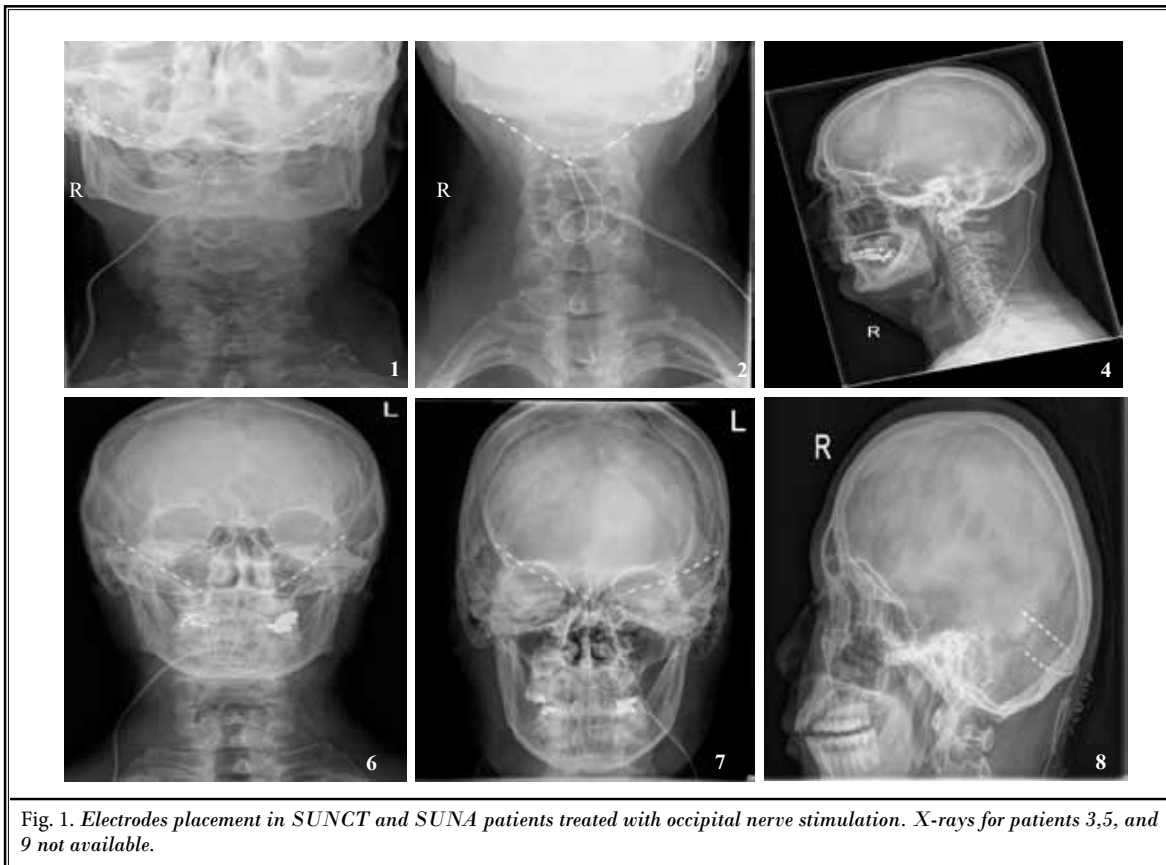


Fig. 1. Electrodes placement in SUNCT and SUNA patients treated with occipital nerve stimulation. X-rays for patients 3, 5, and 9 not available.

was performed under local anesthetic and gentle sedation, with care taken to avoid anesthetizing the occipital nerves. The patient was placed in a lateral position and a sterile field was established. A midline posterior cervical incision was made and bilateral cylindrical-style, octad electrodes (Medtronic, Minneapolis, MN) were introduced using the 2 different techniques illustrated above.

A dual program pulse generator (Medtronic Prime Advanced® Medtronic) was then used to test stimulation and confirm that paresthesias were felt bilaterally. The second part of the insertion was done under a general anesthetic. The electrodes were looped and anchored to the cervical fascia, then tunneled to a lateral cervical or subclavicular skin crease intermediate incision. A left subclavicular or abdominal incision was made (according to the patient's preference) to form a pocket to implant the pulse generator. Electrodes were tunneled to the intermediate incision and a pair of extension leads (Medtronic) were attached. Silicone sheaths were used to protect the lead connections. A topical antibiotic cover with gentamicin was introduced around the pocket and the incisions were closed.

Patients were provided remote controls and instructed how to use them to communicate with the implanted pulse generators. They could adjust their stimulator settings with the remote control, although the pulse generators were programmed to provide continuous stimulation. Patients could turn the stimulator on or off, and vary the pulse width, frequency, or amplitude, although most of them tended only to vary the amplitude. The polarity of the electrodes was adjusted during follow-up visits to achieve comfortable bilateral paresthesias in the occipital region. Patients remained in the hospital for several days after implantation before being discharged.

### Follow-up and Data Collection

Data were collected prospectively from patients' records, outpatient visits, inpatient admissions, mail, and telephone and included demographics, diagnosis, previous and current treatments, ONS settings, pre- and postimplantation headache characteristics, patients' estimates of change in headaches, and complications.

Patients were asked to fill in a headache diary in order to record the frequency, severity on a verbal rating scale (VRS; 0 = no pain to 10 = very severe pain) and duration of attacks for 4 weeks before implantation and 2 weeks prior to each postoperative outpatient follow-up visit. These sessions were scheduled every 3 months for the first year and every 6 months thereafter. Extra

visits or phone consultations were scheduled as required. These prospectively collected data were used at each follow-up to calculate a "headache score," which has been validated elsewhere (24), using the following formula:  $\Sigma$  (duration X severity) of each attack for a 2 week period. This score takes into account not only changes in the frequency of attacks, but also any variation in severity and duration of attacks, giving a comprehensive measure of the response to the treatment.

Since specific tools for measuring the disability of TACs have not been validated yet, disability was assessed and monitored using the Migraine Disability Assessment Scale (MIDAS) (25) and the Headache Impact Test-6 (HIT-6) (26). MIDAS and HIT-6 have been used extensively to assess primary headache disorders and have already been used to assess the disability of patients with CH and hemicrania continua (HC) treated with ONS (15,18). As per the recommendations by Leone et al (27), quality of life and mental state were assessed pre- and postsurgery. The Short Form 36 (SF-36) was used to assess health-related quality of life at baseline and after stable improvements in those who responded, or after a year of continuous stimulation in those who did not respond (28). The Hospital Anxiety (HAD-A) and Depression (HAD-D) scales (29) were used to evaluate the presence and degree of anxiety and depression before and after surgery.

All data were collated at baseline and after every postoperative follow-up in an electronic database (Microsoft Excel® spreadsheet, Microsoft Corporation, Redmond, WA).

### RESULTS

Five women and 4 men with a median age at the operation of 52 years (range: 33–74 years) received stimulator implants (Table 2). Six patients had SUNCT and 3 had SUNA. The median duration of the disorder was 7 years. Three SUNCT and one SUNA patient presented with the episodic form, which subsequently evolved into the chronic form. The remaining patients were chronic from the onset. The median duration of the chronic phase was 4 years. Table 1 shows the headache frequency, severity, and duration characteristics as reported by the patients prior to ONS. All patients had a brain magnetic resonance imaging scan which revealed evidence of ipsilateral neurovascular conflict in 2 patients (Cases 1 and 6).

All patients failed to obtain sustained or substantial benefit from preventive medications administered as single or combination therapy, as well as from drugs

Table 2. Patient demographics.

|                | Age (Years) at Time of implant | Gender | Subtype of Diagnosis    | Duration From Onset to Time of Implant (Years) | Duration of Chronic Phase at Time of Implant (Years) |
|----------------|--------------------------------|--------|-------------------------|--|--|
| 1              | 74                             | M      | Secondary chronic SUNCT | 7  | 4  |
| 2              | 61                             | F      | Primary chronic SUNA    | 4  | 4  |
| 3              | 44                             | M      | Primary chronic SUNCT   | 7  | 7  |
| 4              | 52                             | M      | Secondary chronic SUNCT | 17   | 9  |
| 5              | 53                             | F      | Secondary chronic SUNCT | 7  | 4  |
| 6              | 56                             | M      | Primary chronic SUNCT   | 8  | 8  |
| 7              | 34                             | F      | Primary chronic SUNA    | 2  | 2  |
| 8              | 33                             | F      | Secondary chronic SUNA  | 6  | 3  |
| 9              | 49                             | F      | Primary chronic SUNCT   | 22   | 22   |
| Median (Range) | 52 (33-74)                     |        |                         | 7 (2-22)                                       | 4 (2-22)   |

F: female; M: male; Primary chronic: chronic form of disorder from onset; Secondary chronic: episodic form of disorder that subsequently evolved into chronic form; SUNA: short-lasting unilateral neuralgiform headache attacks with cranial autonomic features; SUNCT: short-lasting unilateral neuralgiform headache attacks with conjunctival injection and tearing

such as pregabalin, mexiletine, and melatonin, which although lacking published evidence of efficacy, can occasionally be effective in these disorders (Table 3). All patients showed a very good, albeit short-lived, response to intravenous lidocaine, while only 3 patients obtained transient benefit from GONI. Five patients had a single-blinded placebo-controlled indomethacin test and 4 had a course of oral indomethacin at doses of 150 to 225 mg daily, showing no effect on their SUNCT/SUNA attacks. Seven patients tried subcutaneous sumatriptan 6 mg or high-flow oxygen inhalation or both to abort their SUNCT/SUNA attacks without any appreciable benefit (Table 4).

The characteristics of SUNCT and SUNA attacks pre- and post-ONS, derived from prospective diaries, are listed in Table 5. At a median follow-up of 38 months (range 24-55 months) after the stimulator implantation, 8 of the 9 patients (89%) reported a marked improvement of their condition. Four of 9 patients became and remained completely pain-free for the whole duration of the follow-up except when the stimulator was switched off or malfunctioned. Four patients reported a marked improvement in their condition but were not rendered pain-free. Two of these 4 patients estimated that their headaches had improved by 95%, while the headache score, derived from the prospective headache diaries, showed an improvement of 97% and 98% in these patients. The other 2 patients estimated that their headaches had improved by 50-60%, though the headache scores revealed an improvement of 81% and

96%. One patient did not report any benefit from the stimulator at 24 months' follow-up and opted to have the ONS explanted. All patients, except the one who failed to respond, would recommend the use of ONS to another patient in a similar situation.

There was a marked improvement in health-related quality of life, disability, and affective scores following ONS. The median baseline scores in all SF-36 domains were low, particularly in role functioning-physical (RP), bodily pain (BP) and social functioning (SF). Following ONS, patients reported a remarkable improvement in all 8 domains, with mean scores similar to the British normative SF-36 mean scores for adults aged 55-64 years old (30) (Table 6).

The median baseline MIDAS and HIT-6 scores were 182 (range 150-270) and 74 (range 68-78), respectively; these scores are consistent with severe disability. When the response to ONS had reached a plateau, the median MIDAS and HIT-6 scores had reduced to 20 (range 0-180) and 52 (range 36-78), respectively, which are consistent with moderate disability. The anxiety (HAD-A) and depression (HAD-D) scores were within the severely impaired range for the majority of patients at baseline. Following ONS, the median HAD-A score reduced from 13 (range 8-16) to 6 (range 0-18) while the median HAD-D score reduced from 11 (range 8-16) to 5 (range 0-16).

Patients who responded to ONS were able to discontinue or reduce their preventive medications for SUNCT/SUNA. Six of the 9 patients were able to discon-

## Occipital Nerve Stimulation in the Treatment of SUNCT and SUNA

Table 3. Preventive treatments tried in patients with SUNCT and SUNA without significant improvement and respective doses (total mg/d).

|   | Lamotrigine | Topiramate | Gabapentin | Pregabalin | Carbamazepine | Oxcarbazepine | Mexiletine | Melatonin | Other Drugs (mg/d)  |
|---|-------------|------------|------------|------------|---------------|---------------|------------|-----------|---|
| 1 | 350         | 175        | 4500       | 500        | NK            | NT            | NT         | 12        | Amitriptyline (NK)<br>Lithium (NK)  |
| 2 | 300         | 700        | 2400       | 350        | 1600          | NT            | 1200       | 9         | Amitriptyline 25<br>Tizanidine (NK)                                       |
| 3 | 400         | 200        | 3600       | 600        | NK            | NK            | NT         | NT        | Amitriptyline 20<br>Sertraline 100  |
| 4 | 300         | 75         | 900        | 300        | NT            | 1200          | NT         | 12        | Sodium valproate 600<br>Propranolol (NK)                                  |
| 5 | 400         | 150        | 3000       | 600        | NK            | 1500          | 600        | 9         | Phenytoin (NK)<br>Propranolol 120   |
| 6 | 50          | 125        | 3000       | 300        | 300           | NT            | NT         | 12        | Lofepamine 70<br>Sodium valproate 600<br>Pizotifen 1.5<br>Propranolol 160 |
| 7 | 250         | 150        | 3600       | 600        | NT            | 1500          | NT         | 15        | Amitriptyline 50<br>Sodium valproate 1000                                 |
| 8 | 200         | 200        | 3600       | 400        | NT            | 1200          | NT         | 12        | Amitriptyline 50<br>Pizotifen 3   |
| 9 | 500         | 400        | 3600       | 600        | NK            | 2400          | 1200       | NT        | Amitriptyline 150<br>Sodium valproate 800                                 |

For this group, side-effects were the usual reason for not attaining maximum doses. NK: dose not known; NT: not tried

Table 4. Acute and transitional treatments tried for SUNCT and SUNA and therapeutic responses.

|   | Indomethacin<br>(Duration of<br>Trial) | High-flow<br>Oxygen | Sumatriptan<br>s.c. 6 mg | Lidocaine infusion (given over 7-10 days) |                 |  | GON injection (lidocaine and steroids) |                      |                         |
|---|--|---------------------|--------------------------|---|-----------------|--|--|----------------------|-------------------------|
|   |  |                     |                          | SUNCT/SUNA<br>Improvement                 | Number<br>Given | Duration of<br>Response                      | SUNCT/SUNA<br>Improvement              | Side of<br>Injection | Duration of<br>Response |
| 1 | 225 mg<br>(2 weeks)                    | Ineffective         | Ineffective              | Pain free                                 | 2               | During infusion<br>only                      | Yes                                    | Rx2                  | 3 days/no<br>response   |
| 2 | 225 mg<br>(3 weeks)                    | Ineffective         | Ineffective              | Pain free                                 | 1               | During infusion<br>only                      | Yes                                    | Lx2                  | 5 days/no<br>response   |
| 3 | 150 mg<br>(2 weeks)                    | NT                  | NT                       | Moderate<br>improvement                   | 1               | During infusion<br>only                      | No                                     | R                    | -                       |
| 4 | 225 mg<br>(4 weeks)                    | Ineffective         | Ineffective              | Pain free                                 | 1               | During infusion<br>only                      | No                                     | L                    | -                       |
| 5 | 100 mg<br>(indo-test)                  | NT                  | NT                       | Pain free                                 | 1               | During infusion<br>only                      | NT                                     | -                    | -                       |
| 6 | 100 mg<br>(indo-test)                  | NT                  | Ineffective              | Moderate<br>improvement                   | 1               | During infusion<br>and 2 weeks<br>afterwards | Yes                                    | Rx2                  | 3 days/no<br>response   |
| 7 | 100 mg<br>(indo-test)                  | Ineffective         | Ineffective              | Moderate<br>improvement                   | 1               | During infusion<br>only                      | NT                                     | -                    | -                       |
| 8 | 100 mg<br>(indo-test)                  | Ineffective         | Ineffective              | Moderate<br>improvement                   | 1               | During infusion<br>only                      | No                                     | L                    | -                       |
| 9 | 200 mg<br>(indo-test)                  | Ineffective         | NT                       | Pain free/<br>Moderate<br>improvement     | 4               | During infusion<br>only                      | No                                     | R                    | -                       |

Indo-test: double blinded intramuscular indomethacin vs normal saline 22; NT: not tried as declined by patient; s.c.: subcutaneous

continue all preventive treatments. One patient (Case 7) was able to maintain significant improvement of her SUNA with a slight reduction of the doses of lamotrigine from 250 mg (pre-ONS) to 100 mg (post-ONS) and oxcarbazepine from 1,500 mg (pre-ONS) to 1,200 mg

(post-ONS), but further reduction led to recrudescence of attacks; he therefore opted to continue on the reduced doses of these agents. Case 5 reported a marked benefit with ONS but was unable to reduce the dose of mexiletine (600 mg) without a worsening of attacks.

Table 5. Effect of occipital nerve stimulation on SUNCT/SUNA attack frequency, severity, and duration.

|                | Follow-up After ONS (Months) | Median Frequency/d (Range) |                    | Median Severity on VRS (Range) |           | Median Duration in Seconds (Range) |              | Daily Headache Score |       | Percentage of Improvement of the Headache | Patients' Estimation of Benefit Since |
|----------------|------------------------------|----------------------------|--------------------|--------------------------------|-----------|------------------------------------|--------------|----------------------|-------|---|---------------------------------------|
|                |                              | Before                     | After              | Before                         | After     | Before                             | After        | Before               | After |   |                                       |
| 1              | 43                           | 46 (0-97)                  | Pain free          | 7 (3-10)                       | Pain free | 660 (120-900)                      | Pain free    | 50135                | 0     | 100%                                      | 100%                                  |
| 2              | 55                           | 33 (8-52)                  | Pain free          | 10 (7-10)                      | Pain free | 240 (120-600)                      | Pain free    | 15904                | 0     | 100%                                      | 100%                                  |
| 3              | 24                           | 30 (16-40)                 | Pain free          | 9 (7-10)                       | Pain free | 32 (20-1920)                       | Pain free    | 13741                | 0     | 100%                                      | 100%                                  |
| 4              | 52                           | 12 (3-20)                  | 1 (0-2)            | 7 (5-10)                       | 5 (4-8)   | 120 (60-360)                       | 120 (53-360) | 2444                 | 97    | 96%                                       | 60%                                   |
| 5              | 55                           | 90 (48-150)                | 41 (26-50)         | 10 (8-10)                      | 5 (4-10)  | 25 (5-75)                          | 23 (3-68)    | 5592                 | 1075  | 81%                                       | 50%                                   |
| 6              | 38                           | 30 (6-103)                 | Pain free          | 8 (5-10)                       | Pain free | 120 (60-600)                       | Pain free    | 12235                | 0     | 100%                                      | 100%                                  |
| 7              | 28                           | 21 (16-42)                 | 7 (0-12)           | 7 (5-8)                        | 5 (3-8)   | 5 (1-1800)                         | 5 (1-20)     | 1920                 | 64    | 97%                                       | 95%                                   |
| 8              | 28                           | 79 (5-154)                 | 9/week (6-12/week) | 10 (7-10)                      | 8 (6-10)  | 120 (5-600)                        | 120 (5-240)  | 15049                | 287   | 98%                                       | 95%                                   |
| 9              | 24                           | 72 (18-96)                 | 74 (15-91)         | 10 (6-10)                      | 10 (6-10) | 10 (5-1800)                        | 10 (5-1500)  | 11038                | 11019 | 0%  | 0%                                    |
| Median (range) | 38 (24-55)                   | 33 (0-154)                 | 1 (0-97)           | 9 (3-10)                       | 5 (3-10)  | 120 (5-1800)                       | 5 (1-1500)   | 12235                | 64    | 98% (Mean 87%)                            | 99% (Mean 78%)                        |

VRS: Verbal rating scale (0 = no pain to 10 = very severe pain); The Headache score was derived from the two week diaries patients kept prospectively at baseline and prior to each assessment using the formula:  $\Sigma$  [duration (mins) X severity (VRS)]

Table 6: Effect of occipital nerve stimulation on health-related quality of life

|    | SUNCT/SUNA patients                  |                                       | British Normative Data Mean $\pm$ SD |
|----|--------------------------------------|---------------------------------------|--------------------------------------|
|    | Pre-ONS Mean $\pm$ SD Median (Range) | Post-ONS Mean $\pm$ SD Median (Range) |                                      |
| PF | 52 $\pm$ 22<br>60 (30-85)            | 79 $\pm$ 26<br>85 (30-100)            | 80 $\pm$ 22                          |
| RP | 0 $\pm$ 0<br>0 (0)                   | 64 $\pm$ 48<br>100 (0-100)            | 79 $\pm$ 36                          |
| BP | 4 $\pm$ 5<br>0 (0-10)                | 60 $\pm$ 37<br>50 (10-100)            | 79 $\pm$ 24                          |
| GH | 30 $\pm$ 28<br>10 (10-80)            | 71 $\pm$ 18<br>70 (40-100)            | 68 $\pm$ 23                          |
| V  | 27 $\pm$ 28<br>10 (0-60)             | 59 $\pm$ 30<br>75 (0-80)              | 63 $\pm$ 20                          |
| SF | 14 $\pm$ 20<br>0 (0-50)              | 75 $\pm$ 37<br>100 (0-100)            | 87 $\pm$ 23                          |
| RE | 33 $\pm$ 33<br>33 (0-100)            | 81 $\pm$ 38<br>100 (0-100)            | 86 $\pm$ 30                          |
| MH | 35 $\pm$ 22<br>44 (0-64)             | 77 $\pm$ 34<br>88 (0-100)             | 78 $\pm$ 17                          |

PF: Physical Functioning; RP: Role Functioning-Physical; BP: Bodily Pain; GH: General Health; VT: Vitality; SF: Social Functioning; RE: Role Functioning-Emotional; MH: Mental Health.

Most patients obtained a clear benefit from the stimulator after a few days (median 11 days), though it took a few months to achieve maximum improvement (median 3.5 months). To ensure that the clinical improvement was related to ONS, the stimulator was switched off (with patient consent) in Patients 1, 3 and 5, which in all cases led to a worsening of the attacks within 48 hours. There was also worsening of the headaches in Patients 1, 2, 4, and 7 following battery failure; in most cases this was experienced within 1-5 days of failure though, interestingly, Case 2 remained pain-free for 3 months after the battery ran out, following 34 months of continuous stimulation. Case 9, who was unresponsive to ONS, did not report any change in her headache when the stimulator was switched off. The other 2 patients declined to switch the stimulator off.

The range of stimulation parameters and the patterns of use are reported in Table 7. The stimulator was switched on continuously in all patients. The patients experienced occipital paresthesia, which is known to be a requirement for clinical effect.

Four patients reported adverse events from ONS (Table 7). Electrode migration was noted in one patient (Case 4), which led to a marked worsening of the



headache. Interestingly, a month after surgery, Case 1 developed a continuous background pain of moderate intensity at the same site as the SUNCT attacks, with superimposed exacerbations of up to an hour associated with ipsilateral conjunctival injection and lacrimation. A diagnosis of HC was confirmed by a double-blind indo-test. The patient was started on oral indomethacin and became completely pain-free, but the HC recurred every time reduction of the indomethacin dose was attempted. Case 9 had lead site pain and variable occipital paresthesia which failed to improve despite trials of various stimulation parameters. She opted to have the ONS explanted after 24 months as she had not derived any benefit. In Patients 1, 2, 4, and 7 the battery discharged after 23, 34, 26, and 25 months, respectively. In these cases the battery was replaced with a rechargeable one (Restore Advanced®, Medtronic).

**DISCUSSION**

This is the first case series that provides evidence for long-term effectiveness of occipital nerve stimulation in medically intractable SUNCT and SUNA. The remarkable improvement obtained by 8 out of 9 patients provides evidence, albeit on an open-label-basis, that ONS may have a role in the management of chronic, medically refractory SUNCT and SUNA. This is borne out by the substantial reduction in disability and improvement of quality of life and affective scores seen in these responders. Additionally, most of the responders were able to stop or reduce preventive medications for SUNCT or SUNA.

A limitation of this observational study is the absence of a control group, raising the possibility that the effect of ONS in this patient group might be attributable to placebo or natural history. However, blinding with ONS is particularly challenging since it seems that occipital paresthesia is a requirement for clinical effect. Several observations in this report suggest more than natural history or a placebo effect, including: a protracted preceding chronic phase, lack of response to several other treatments, the relatively robust response rate, sustained long-term improvement, and the rapid deterioration and recovery after technical failures.

A particular strength of this study is the relatively long duration of follow-up. In most of the series published hitherto, patients were followed for a period ranging from 13.5 to 17.5 months (31,16,18). The importance of long-term follow-up was highlighted by Fontaine et al (17) who, in a series of 13 chronic cluster headache patients treated with ONS, reported a patient who completely lost therapeutic benefit initially obtained with ONS at 16 months follow-up. The results of our series indicate a robust and long-lasting improvement from continuous stimulation over a median follow-up period of 38 months. With the stimulator working properly, none of our patients reported a loss of the improvement achieved, suggesting that ONS has a long-lasting reliability and consistency in this patient group.

Other series of occipital nerve stimulation for headache report that it is a relatively safe procedure with no reports of any serious adverse events. Common

Table 7. Occipital nerve stimulation parameter settings and complications.

|   | Amplitude (V) | Frequency (Hz) | Pulse Width (µs) | Complications  | Action Taken   |
|---|---------------|----------------|------------------|--|--|
| 1 | 1.9-3.1       | 100            | 450              | -New onset of HC<br>-Infection over the ONS scar site<br>-Battery discharged after 23 months       | -Started indomethacin 150 mg/day<br>-Resolved with oral antibiotics<br>-Replaced with a rechargeable battery |
| 2 | 0.8           | 60             | 450              | -Battery discharged after 34 months  | -Replaced with a rechargeable battery  |
| 3 | 1.0-1.8       | 70             | 450              | None   |  |
| 4 | 1.5-2.5       | 70             | 450              | -Electrode migration<br>-Skin erosion and exposed electrode<br>-Battery discharged after 26 months | -Surgical revision<br>-Surgical revision<br>-Replaced with a rechargeable battery                            |
| 5 | 0.9-1.6       | 100            | 450              | -None  |  |
| 6 | 0.3           | 130            | 450              | -None  |  |
| 7 | 1.5-3.2       | 70             | 450              | -Battery discharged after 25 months  | -Replaced with a rechargeable battery  |
| 8 | 0.4-2.1       | 65             | 450              | -Moderate neck stiffness. Severe pulling pain over the leads due to muscle recruitment             | - Surgical revision  |
| 9 | 0.4-1.3       | 30-130         | 450              | -Lead site pain and variable paraesthesias over the occiput  | -No improvement after various trials of different stimulation parameters; ONS explanted after 24 months      |

complications reported include electrode migration, lead site pain, myofascial incision site pain, neck stiffness, discharged battery, battery site pain, and contact dermatitis. In this case series with a median follow-up of 38 months, there were a range of complications including electrode migration, skin erosion resulting in electrode exposure, infection, lead site pain, muscle recruitment, and neck stiffness. Four of the 9 patients needed a new battery during the follow-up period. Battery depletion is not strictly a complication but it does require a further operation. However, given the recent availability of rechargeable batteries, the need for repeat operations for new batteries in the future will be reduced.

There is sparse literature on the ability of a percutaneous trial to predict the long-term benefit of an ONS implant (31). There are 3 multicenter randomized control trials of ONS in primary headaches, all of which have been conducted in chronic migraine (19,20,32). A subgroup analysis of data from the PRISM study reported that a favorable response to a percutaneous treatment trial was moderately predictive of a 12-week response (32). However, this study has only been reported in abstract form and just the short-term data are available, making it difficult to ascertain the actual importance of trial stimulation in predicting a response to ONS. Moreover, it is arguable that longer periods of stimulation in those who failed the trial might have resulted in a benefit in the longer term, given that ONS usually induces improvements over weeks or months (17). A large randomized controlled trial of ONS in 177 patients with chronic migraine reported that 89% of them demonstrated a favorable response to a percutaneous trial; these patients then had a permanent device implanted, but only 17% responded favorably (defined as a > 50% reduction in mean visual analog score [VAS]) at 12 weeks (20). It is interesting to compare this with the ONSTIM study of ONS in chronic migraine, in which all patients had permanent implants, without percutaneous trial stimulation. This study reported that 39% of them responded favorably (defined as a > 50% reduction in headache days or > 3 point reduction in VAS) at 12 weeks (19).

The open-label series of ONS in headache disorders also report a relatively high response (> 80%) to trial stimulation (15,31,33,34), in keeping with response rates reported in randomized controlled trials. This reported benefit of a short percutaneous trial might represent a placebo effect in a cohort of patients who have high expectations from surgery after failing most

available treatments. However, the ability of a trial test to select long-term favorable responders appears poor in controlled studies, especially given that more than 80% of patients go onto full implantation anyway. In our study, the majority of patients obtained a significant response after a median of 3.5 months from the implant. By using a 1–2 weeks trial, we would have excluded patients that would have benefited from ONS. Hence, a stimulation trial does not appear to be a reliable predictor of long-term success with ONS in headache disorders. Larger prospective ad hoc studies are needed to further clarify this issue.

Likewise, GONI has been shown not to be a predictor of favorable response to ONS in patients with medically intractable, chronic primary headaches (16,35). In our study, GONIs were performed in 7 out of 9 patients (Table 4). Three (Patients 1, 2, 6) out of 7 patients responded to the first procedure, but did not derive any improvement from the second one. They all became pain-free with ONS. Among those who did not respond favorably to GONI (Patients 3, 4, 8, 9), 3 patients obtained a favorable response from ONS (respectively 100%, 96%, and 98% improvement of the headache score), whereas one patient did not respond favorably to ONS treatment. This data suggest that also for SUNCT and SUNA syndromes, the response to GONI cannot be considered a predictor of the therapeutic effect from ONS.

The overall robust effectiveness and relatively good tolerability of ONS might suggest its use as a first-line surgical option in medically intractable, chronic SUNCT and SUNA at this stage. Data on other surgical options for these disorders are poor and mostly based on single case reports or small series of patients with only short-term follow-up. Encouraging results have been recently reported in a series of 9 patients with chronic, medically refractory SUNCT and SUNA who had a vascular loop in contact with the trigeminal root entry zone ipsilateral to the site of the pain and underwent microvascular decompression (MVD) of the trigeminal nerve (5). However, ONS may be preferable to MVD given the overall superior effectiveness shown in our study and the low risk of severe complications, which can potentially occur after MVD of the trigeminal nerve (36). Likewise, ONS may be a better option for older persons who could not tolerate a major invasive operation and for patients who suffer from alternating side headache attacks. While ONS can theoretically be used in every patient, only patients with a demonstrable trigemino-vascular conflict ipsilateral to the pain would be suit-

able for MVD. Although a recent study suggested that a relatively high proportion of patients with SUNCT and SUNA have ipsilateral trigemino-vascular conflict, these data need to be verified in a larger study (4). On the other hand, ONS is a relatively expensive procedure compared to MVD; hence it may still be reasonable to consider MVD in patients with neurovascular conflict, though more long-term efficacy data from larger series are required for both procedures.

Based on the finding of posterior hypothalamic region activation in SUNCT, 3 patients who had medically refractory SUNCT have been treated with posterior hypothalamic DBS (11-13). The patients were reported to have good outcomes and the procedure was well tolerated. Nevertheless, more data are required before hypothalamic-region DBS can be routinely recommended, especially given the small risk of fatal complications (14).

The exact mechanism of action of ONS in primary headache disorders is still unknown. Based on the experience in CH, some authors have suggested that the stimulator might act by modulating supraspinal structures involved in central nociception processing, such as the trigemino-cervical complex and central structures of the pain neuromatrix, through slow neuroplastic changes (37). This would explain the delayed therapeutic effect of ONS observed in most chronic cluster headache (CCH) patients. This hypothesis was recently supported by a fluorodeoxyglucose-positron emission tomography (FDG-PET) study conducted in patients with CCH who underwent ONS. It showed a normalization of several hypermetabolic areas of the neuromatrix after a few months of stimulation (38). The study also suggested that ONS acts merely as a symptomatic treatment, given its inability to reduce hypothalamic hyperactivity, which is typically found during attacks in episodic cluster headache.

SUNCT/SUNA have clinical and pathophysiological features that overlap with CH (39) and trigeminal neuralgia (4,5), suggesting an underlying complex pathophysiology characterized by an interaction between peripheral and central structures of the brain. Patients with SUNCT and SUNA treated with ONS showed better outcomes, compared to the series of patients with CH already published, in terms of a higher proportion of those who responded favorably ( $n = 8/9$  [89%] in our series versus  $n = 61/91$  [67%] in CH series) as well as rate and degree of improvement (21). This effect might reflect differences in the biology of SUNCT/SUNA and CH,

with the former possibly characterized by a prominent involvement of more peripheral areas of the nociceptive system. Furthermore, besides a slow neuromodulatory process of areas belonging to the pain matrix, which has been suggested to be the main mechanism of action of ONS in primary headaches (38,40), a plastic modulation of structures, like the trigeminocervical complex, might explain the rapid and substantial improvement observed in the majority of patients with SUNCT and SUNA.

In conclusion, this study shows a beneficial response to ONS in patients with chronic, medically intractable SUNCT or SUNA which then continued over a median follow-up of 38 months. There was a substantial reduction in headache-related disability and improvement of affective symptoms. The stimulator proved to be safe and generally well tolerated. Given the potential adverse events of other surgical procedures and their inconsistent results, ONS might be considered the surgical option of choice for medically intractable, chronic SUNCT and SUNA. The efficacy of ONS in SUNCT and SUNA further extends the potential therapeutic spectrum of action of this surgical procedure, strengthening its role in the management of chronic, medically refractory primary headache disorders.

#### **AUTHOR CONTRIBUTIONS**

MM, PS, LW, and GL participated in the conception and design of this study. LW did the procedures. MM and GL acquired the data. MM, GL, PS, and LW analyzed and interpreted the data. GL drafted the manuscript. MM, PS, and LW revised the manuscript content. MM supervised the study.

#### **Conflicts of Interest**

GL and PS have no disclosures. MSM serves on the advisory board for Allergan and St. Jude Medical, and has received payment for the development of educational material from Allergan, Merck Sharpe and Dohme Ltd, and Medtronic. LW has acted as advisor for Medtronic, Codman, and St. Jude Medical. LW has received honoraria for lectures from Medtronic and St. Jude Medical. LW is named on a patent application concerning anchoring techniques for occipital nerve stimulators. Some research within the department where LW works is sponsored by a grant from B Braun. This work was undertaken at UCL/UCLH and was funded in part by the Department of Health NIHR Biomedical Research Centres funding scheme.

## REFERENCES

1. Headache Classification Subcommittee of The International Headache Society. The International Classification of Headache Disorders 2nd edition. *Cephalalgia* 2004; 24 (Supplement 1):1-195.
2. Cohen AS, Matharu MS, Goadsby PJ. Short-lasting unilateral neuralgiform headache attacks with conjunctival injection and tearing (SUNCT) or cranial autonomic features (SUNA)--a prospective clinical study of SUNCT and SUNA. *Brain* 2006; 129:2746-2760.
3. Cohen AS. Short-lasting unilateral neuralgiform headache attacks with conjunctival injection and tearing. *Cephalalgia* 2007; 27:824-832.
4. Williams MH, Broadley SA. SUNCT and SUNA: Clinical features and medical treatment. *J Clin Neurosci* 2008; 15:526-534.
5. Williams MH, Bazina R, Tan L, Rice H, Broadley SA. Microvascular decompression of the trigeminal nerve in the treatment of SUNCT and SUNA. *J Neurol Neurosurg Psychiatry* 2010; 81:992-996.
6. Morales-Asin F, Espada F, Lopez Obarrio LA, Navas I, Escalza I, Iniguez C. A SUNCT case with response to surgical treatment. *Cephalalgia* 2000; 20:67-68.
7. Hannerz J, Linderth B. Neurosurgical treatment of short-lasting, unilateral, neuralgiform hemicrania with conjunctival injection and tearing. *Br J Neurosurg* 2002; 16:55-58.
8. Matharu MS, Cohen AS, Boes CJ, Goadsby PJ. Short-lasting unilateral neuralgiform headache with conjunctival injection and tearing syndrome: A review. *Current Pain and Headache Reports* 2003; 7:308-318.
9. Black DF, Dodick DW. Two cases of medically and surgically intractable SUNCT: A reason for caution and an argument for a central mechanism. *Cephalalgia* 2002; 22:201-204.
10. May A, Bahra A, Buchel C, Turner R, Goadsby PJ. Functional magnetic resonance imaging in spontaneous attacks of SUNCT: Short-lasting neuralgiform headache with conjunctival injection and tearing. *Ann Neurol* 1999; 46:791-794.
11. Leone M, Franzini A, D'Andrea G, Broggi G, Casucci G, Bussone G. Deep brain stimulation to relieve drug-resistant SUNCT. *Ann Neurol* 2005; 57:924-927.
12. Lyons MK, Dodick DW, Evidente VG. Responsiveness of short-lasting unilateral neuralgiform headache with conjunctival injection and tearing to hypothalamic deep brain stimulation. *J Neurosurg* 2009; 110:279-281.
13. Bartsch T, Falk D, Knudsen K, Reese R, Raethjen J, Mehdorn HM, Volkmann J, Deuschl G. Deep brain stimulation of the posterior hypothalamic area in intractable short-lasting unilateral neuralgiform headache with conjunctival injection and tearing (SUNCT). *Cephalalgia* 2011; 31:1405-1408.
14. Schoenen J, Di Clemente L, Vandenhede M, Fumal A, De Pasqua V, Mouchamps M, Remacle JM, de Noordhout AM. Hypothalamic stimulation in chronic cluster headache: A pilot study of efficacy and mode of action. *Brain* 2005; 128:940-947.
15. Schwedt TJ, Dodick DW, Hentz J, Trentman TL, Zimmerman RS. Occipital nerve stimulation for chronic headache--long-term safety and efficacy. *Cephalalgia* 2007; 27:153-157.
16. Burns B, Watkins L, Goadsby PJ. Treatment of medically intractable cluster headache by occipital nerve stimulation: Long-term follow-up of eight patients. *Lancet* 2007; 369:1099-1106.
17. Fontaine D, Christophe Sol J, Raoul S, Fabre N, Geraud G, Magne C, Sakarovich C, Lanteri-Minet M. Treatment of refractory chronic cluster headache by chronic occipital nerve stimulation. *Cephalalgia* 2011; 31:1101-1105.
18. Burns B, Watkins L, Goadsby PJ. Treatment of hemicrania continua by occipital nerve stimulation with a bion device: Long-term follow-up of a crossover study. *Lancet Neurol* 2008; 7:1001-1012.
19. Saper JR, Dodick DW, Silberstein SD, McCarville S, Sun M, Goadsby PJ. Occipital nerve stimulation for the treatment of intractable chronic migraine headache: ONSTIM feasibility study. *Cephalalgia* 2011; 31:271-285.
20. Silberstein SD, Dodick DW, Saper J, Huh B, Slavin KV, Sharan A, Reed K, Narouze S, Mogilner A, Goldstein J, Trentman T, Vaisma J, Ordia J, Weber P, Deer T, Levy R, Diaz RL, Washburn SN, Mekhail N. Safety and efficacy of peripheral nerve stimulation of the occipital nerves for the management of chronic migraine: Results from a randomized, multicenter, double-blinded, controlled study. *Cephalalgia* 2012; 32:1165-1179.
21. Magis D, Schoenen J. Advances and challenges in neurostimulation for headaches. *Lancet Neurol* 2012; 11:708-719.
22. Matharu MS, Cohen AS, McGonigle DJ, Ward N, Frackowiak RS, Goadsby PJ. Posterior hypothalamic and brainstem activation in hemicrania continua. *Headache* 2004; 44:747-761.
23. Goadsby PJ, Schoenen J, Ferrari MD, Silberstein SD, Dodick D. Towards a definition of intractable headache for use in clinical practice and trials. *Cephalalgia* 2006; 26:1168-1170.
24. Levy MJ, Jager HR, Powell M, Matharu MS, Meeran K, Goadsby PJ. Pituitary volume and headache: Size is not everything. *Arch Neurol* 2004; 61:721-725.
25. Stewart WF, Lipton RB, Kolodner K, Liberman J, Sawyer J. Reliability of the migraine disability assessment score in a population-based sample of headache sufferers. *Cephalalgia* 1999; 19:107-114.
26. Kosinski M, Bayliss MS, Bjorner JB, Ware JE Jr, Garber WH, Batenhorst A, Cady R, Dahlöf CG, Dowson A, Tepper S. A six-item short-form survey for measuring headache impact: The HIT-6. *Qual Life Res* 2003; 12:963-974.
27. Leone M, Franzini A, Cecchini AB, Broggi G, Bussone G. Stimulation of occipital nerve for drug-resistant chronic cluster headache. *Lancet Neurol* 2007; 6:289-291.
28. Mueller OM, G. C., Katsarava Z, Diener HC, Sure U, Gasser T. Occipital nerve stimulation for the treatment of chronic cluster headache - lessons learned from 18 months experience. *J Neurol Surg A Cent Eur Neurosurg* 2011; 72:84-89.
29. Mykletun A, Stordal E, Dahl AA. Hospital Anxiety and Depression (HAD) scale: Factor structure, item analyses and internal consistency in a large population. *Br J Psychiatry* 2001; 179:540-544.
30. Jenkinson C, Coulter A, Wright L. Short form 36 (SF36) health survey questionnaire: Normative data for adults of working age. *BMJ* 1993; 306:1437-1440.
31. Palmisani S, Al-Kaisy A, Arcioni R, Smith T, Negro A, Lambro G, Bandikatla V, Carson E, Martelletti P. A six year retrospective review of occipital nerve stimulation practice - controversies and challenges of an emerging technique for treating refractory headache syndromes. *J Headache Pain* 2013; 14:67.
32. Lipton RB, Goadsby PJ, Cady RK, Aurora SK, Grosberg BM, Freitag FG, Silberstein SD, Whiten DM, Jaax KN. PRISM study: Occipital nerve stimulation for treatment-refractory migraine. *Cephalalgia*. 2009; 29(Suppl 1):30.
33. Brewer AC, Trentman TL, Ivancic MG,

- Vargas BB, Rebecca AM, Zimmerman RS, Rosenfeld DM, Dodick DW. Long-term outcome in occipital nerve stimulation patients with medically intractable primary headache disorders. *Neuromodulation*. 2012; Aug 6. [Epub ahead of print].
34. Mueller O, Diener HC, Dammann P, Rabe K, Hagel V, Sure U, Gaul C. Occipital nerve stimulation for intractable chronic cluster headache or migraine: A critical analysis of direct treatment costs and complications. *Cephalalgia*. 2013 Jun 28. [Epub ahead of print].
35. Schwedt TJ, Dodick DW, Trentman TL, Zimmerman RS. Response to occipital nerve block is not useful in predicting efficacy of occipital nerve stimulation. *Cephalalgia* 2007; 27:271-274.
36. Barker FG, Jannetta PJ, Bissonette DJ, Larkins MV, Jho HD. The long-term outcome of microvascular decompression for trigeminal neuralgia. *N Engl J Med* 1996; 334:1077-1083.
37. Paemeleire K, Bartsch T. Occipital nerve stimulation for headache disorders. *Neurotherapeutics* 2010; 7:213-219.
38. Magis D, Bruno MA, Fumal A, Gérardy PY, Hustinx R, Laureys S, Schoenen J. Central modulation in cluster headache patients treated with occipital nerve stimulation: An FDG-PET study. *BMC Neurol* 2011; 11:25.
39. Goadsby PJ, Lipton RB. A review of paroxysmal hemicranias, SUNCT syndrome and other short-lasting headaches with autonomic feature, including new cases. *Brain* 1997; 120:193-209.
40. Matharu MS, Bartsch T, Ward N, Frackowiak RS, Weiner R, Goadsby PJ. Central neuromodulation in chronic migraine patients with suboccipital stimulators: A PET study. *Brain* 2004; 127:220-230.

