

## Occipital Nerve Electrical Stimulation via the Midline Approach and Subcutaneous Surgical Leads for Treatment of Severe Occipital Neuralgia: A Pilot Study

Leonardo Kapural, MD, PhD, Nagy Mekhail, MD, PhD, Salim M. Hayek, MD, PhD, Michael Stanton-Hicks, MB, BS, and Osama Malak, MD

Pain Management Department, The Cleveland Clinic Foundation, Cleveland, Ohio

Persistent occipital neuralgia can produce severe headaches that may not be controllable by conservative or surgical approaches. We describe a case series of 6 patients who had chronic headaches over an average of 4.9 yr who underwent occipital nerve electrical stimulation lead implantation using a modified midline approach. The patients had received conservative and surgical therapies in the past including oral antidepressants, membrane stabilizers, opioids, occipital nerve blocks, and radiofrequency ablations. Significant decreases in pain visual analog scale (VAS) scores and drastic improvement in functional capacity were observed during the occipital stimulation trial

and during the 3-mo follow-up after implantation. The mean VAS score changed from  $8.66 \pm 1.0$  to  $2.5 \pm 1.3$  whereas pain disability index improved from  $49.8 \pm 15.9$  to  $14.0 \pm 7.4$ . Our midline approach has several advantages compared with the submastoid approach used elsewhere. There is only one small midline incision over the upper neck and the strain on the lead extension occurs only with flexion and is minimal with lateral flexion and rotation, which contributes to overall stability of this system.

(Anesth Analg 2005;101:171-4)

Occipital neuralgia is characterized by sharp and/or throbbing pain that starts in the suboccipital region and radiates over the posterior scalp. Known causes include trauma, compression of the upper cervical roots by degenerative changes in the cervical spine, and tumors involving the second and third cervical dorsal roots. Hypesthesia or dysesthesia in the posterior scalp are common accompaniments of severe neuralgia (1). Persistent occipital neuralgia can produce severe headaches that may not be controllable by membrane stabilizers, tricyclic antidepressants, or opioids. Many patients with severe occipital headaches may respond to a series of occipital nerve blocks but not with substantial, long-term pain relief. Therapeutic surgical approaches are associated with mixed results. Partial posterior rhizotomy at C1-3, atlantoepistropheic ligament decompression of the C2 dorsal root ganglion and C2 nerve, and C2 ganglionostomy have all been attempted with variable results and frequent perioperative morbidity (2-4).

The success rates of those studies are difficult to determine, given the small number of patients in the treatment groups (2-14 patients). After partial posterior rhizotomy, 10 of the 14 patients rated pain as good or excellent (2) and, after C2 ganglionostomy, all 4 patients improved. The atlantoepistropheic ligament decompression was successful in 1 of 2 patients (3), whereas 72.2% of the patients reported good or excellent outcome after occipital nerve release but without complete pain relief (4). There are no formal comparisons on those treatment modalities. There has been much interest recently in subcutaneous occipital nerve stimulation for controlling the pain of occipital neuralgia (5) in which percutaneous and surgical spinal cord stimulation leads are used to stimulate the occipital nerve (5-7). Two initial reports [(6,7)  $n = 1$ ,  $n = 12$ , respectively] claimed >50% pain relief at 1 yr follow-up in all of the patients who received percutaneous lead implant via the submastoid approach. After initial enthusiasm for the procedure, there were reports of more than a 50% failure rate, mostly because of dislodgement of the leads and loss of the stimulation field over the affected nerve area (6). We are describing a case series of six of our patients who underwent occipital nerve electrical stimulation lead implantation using a modified approach and bilateral

Accepted for publication December 29, 2004.

Address correspondence and reprint requests to Leonardo Kapural, MD, PhD, Pain Management Center, The Cleveland Clinic Foundation, 9500 Euclid Ave., Desk C25, Cleveland, OH 44195. Address e-mail to kapural@ccf.org.

DOI: 10.1213/01.ANE.0000156207.73396.8E

**Table 1.** Characteristics of Our Six Patients Treated Using Occipital Electrical Stimulation

Patient no.	Age (yr)	Sex	Symptoms	Previous Treatments	VAS pre	VAS post	PDI pre	PDI post	Opioids pre (mg)	Opioids post (mg)
1	47	Female	Head and upper neck pain	Occ. block, cervical facet block/RFA	8	4	32	13	0	0
2	52	Female	Headache	Occ. block, occ. RFA	8	3	35	3	380	280
3	40	Male	Headache, N/V	Occ. block, cervical facet block/RFA	10	3	75	16	60	30
4	72	Male	Head and neck pain	Occ. block, cervical facet block/RFA	10	3	55	26	0	0
5	50	Male	Headache	Occ. block	8	0	57	12	90	0
6	46	Male	Head and neck pain	Atlantoaxial, occ. block, cervical epidural injections	8	2	45	14	0	0

Opioid dosing is expressed as a morphine sulfate per oral equivalent.  
VAS = Visual analog scale, PDI = pain disability index, Occ. = occipital, N/V = nausea/vomiting; RFA = radiofrequency ablation.

**Table 2.** Detailed Pain Disability Index Scoring for Our 6 Patients Before and 3 Months After Implantation of the System

Patient no.	Fam		Rec		Soc		Occ		Sex		Sel		Lif		VAS	
	pre	post	pre	post	pre	post	pre	post	pre	post	pre	post	pre	post	pre	post
1	7	3	8	4	9	2	0	0	0	0	0	0	0	0	8	4
2	9	0	9	0	9	0	0	0	0	0	0	0	0	0	8	3
3	9	3	10	4	10	2	9	4	9	0	9	0	9	0	10	3
4	8	4	7	4	9	2	10	10	0	0	9	3	2	0	10	3
5	8	2	8	4	8	4	8	2	0	0	8	0	9	0	8	0
6	7	5	7	5	7	2	8	0	0	0	3	0	5	0	8	2

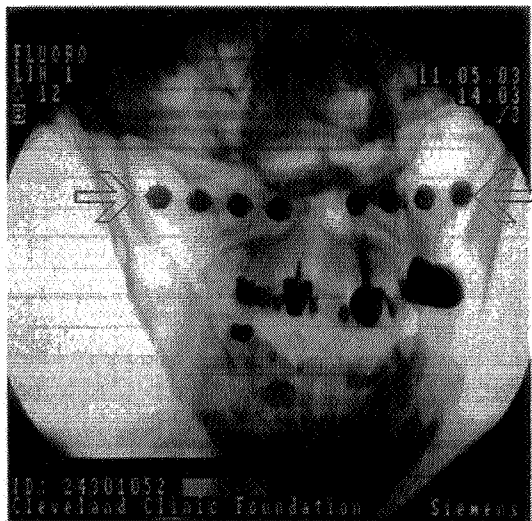
The categories include activities related to home and family (Fam), recreation (Rec), social activities such as those involving friends and acquaintances (Soc), occupation (Occ), sexual behavior (Sex), self-care which includes activities such as driving, getting dressed, and taking a shower (Sel), life-support activities such as eating and sleeping and pain intensity index on VAS (visual analog scale) (8) (Lif). Please note a significant improvement in almost every category scored by the patients.

surgical Resume (Medtronic, Minneapolis, MN) leads. The technique, degree of pain relief, and improvement in functional capacity are described.

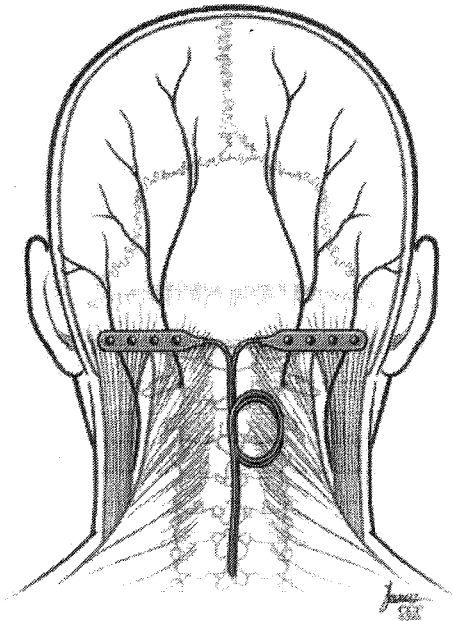
## Methods

We implanted six subcutaneous occipital peripheral nerve stimulation systems using surgical leads. IRB permission and patient consent to perform this study were obtained. All patients were referred to our pain clinic for treatment of severe occipital neuralgia. They were treated for at least 6 mo using membrane stabilizers, antidepressants, and opioids. Prior treatments included C2 posterior ramus block as well as greater and lesser occipital nerve block, and some patients received radiofrequency ablation of the greater occipital nerve, all with short-lived pain relief (Table 1). An occipital nerve stimulation trial was completed after psychological evaluation and approval by our internal committee for implantable devices. Those 4 men and 2 women underwent 7-15 days of greater and/or lesser occipital nerve stimulation trials. All trials were completed using percutaneous Quad (Medtronic) leads positioned across the level of C1 viewed posterior-anteriorly using fluoroscopy.

All implants were completed under monitored anesthesia care using midazolam, fentanyl, and propofol infusion with intermittent boluses. Patients were positioned prone with support under the chest and forehead, and prepared and draped over the occipital area, neck, and parts of the upper and lower back and left or right upper buttock. Two initial incisions were then made: one in the nuchal region 1 in. in length, positioned cranio-caudal for bilateral lead implants, and another 2 in. over the right or left upper buttock for the generator implant. Subcutaneous blunt dissection was then completed from the midline bilaterally at the level of C1-2 and a pocket was created using a "hockey stick like" plastic introducer in the shape of the surgical lead. Leads were then positioned and the patient awakened for the intraoperative trial of stimulation (Fig. 1, A and B). After complete coverage in the painful occipital area was confirmed by the patient, leads were then anchored in position subcutaneously. A "strain release" loop was fashioned at the implant site. This was loosely sutured at three points to the subcutaneous tissue, the intention being to reduce tension on the lead during flexion. The pulse generator was joined to the two leads by extension cables that were drawn through a subcutaneous tunnel and placed in a pocket in the buttock.



A



B

**Figure 1.** Radiograph (A) and schematics (B) of the midline subcutaneous approach in surgical lead positioning for electrical stimulation of the occipital nerve. A, Bilateral position of subcutaneous Resumé leads (arrows) after initial adjustment and just before intraoperative stimulation testing. Note that both leads are at the level of C1-2 dens and aimed laterally. B, Schematic of the lead positioning in the subcutaneous occipital area. Note that the lead cable extensions form the loop just below the implant's position and via the same midline incision.

Stimulation variables used for the occipital nerve stimulation are similar to those used for spinal cord stimulation. We used a pulse width from 200 to 400  $\mu$ s, rate of 30-100 per minute, and amplitude from 1.5 to 5 V.

Patients were followed for 3 mo using the pain disability index (PDI) questionnaires before implant and at 3 mo after implant (8). The disability scale is

composed of 8 subscales: visual analog scale (VAS) pain score, sexual behavior, family and home duties, recreation, occupation, self-care, social, and basic life functions disabilities. Each of these individual scales ranges from 0 to 10, with 10 indicating the highest level of disability (8). To obtain the PDI, we added the responses to the 8 subscales for each time point (Table 2). A score of 80 of PDI would indicate the maximal level of disability.

For all scales, we assessed whether there was an overall change in scores at two time points using Wilcoxon's signed rank test.

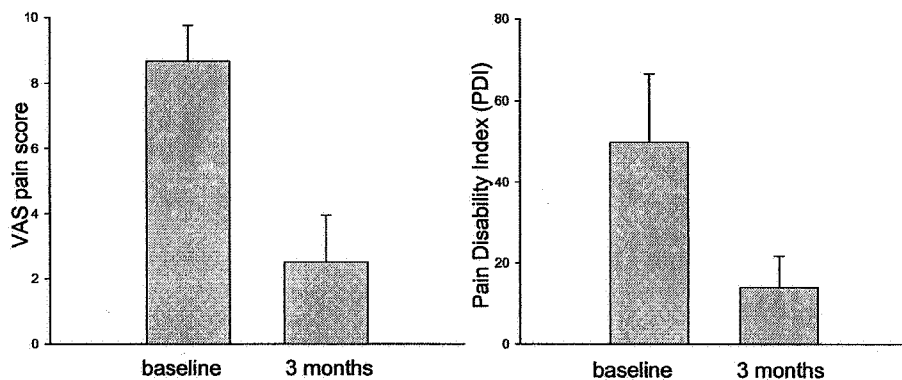
## Results

The average age of the patients was  $51.8 \pm 12.3$  yr. They had had chronic occipital headaches for 4.9 yr. Significant decreases in pain VAS scores were measured at 3 mo after occipital stimulation system implant ( $P < 0.0001$ ) with the mean VAS score change from  $8.66 \pm 1.0$  to  $2.5 \pm 1.3$  (Fig. 2, Tables 1 and 2). At the 3-mo check after the procedure, PDI improved significantly ( $P < 0.0005$ ; Fig. 2) from  $49.8 \pm 15.9$  to  $14.0 \pm 7.4$ , suggesting a drastic improvement in functional capacity in our 6 patients. There were no technical difficulties and the stimulation system was left fully implanted subcutaneously.

## Discussion

We describe a pilot series of 6 patients with significant improvement in pain and functional capacity after implantation of a peripheral nerve stimulation system for severe occipital neuralgia (Tables 1 and 2). To reiterate, this patient group had been unresponsive to all prior conservative and interventional procedures and uniformly had had uncontrolled occipital headaches despite increasing dosages of membrane stabilizers, antidepressants, and opioids. Selected flat "paddle" surgical-type leads allow better current distribution and fewer current surges which may occur when smaller percutaneous leads are used. We believe that such an approach would provide a more even and possibly consistent stimulation.

Our midline approach has several advantages compared with the submastoid approach used elsewhere. First, only one small midline incision over the upper neck is used to achieve stimulation of one or both greater occipital nerves. This approach also can be used to include the lesser occipital and posterior auricular nerves. Second, lead dislodgement may be less frequent for two reasons: the strain on the lead extension occurs only with flexion and is minimal or nonexistent with lateral flexion and rotation of the neck, and the loose lead extension loop positioned in subcutaneous tissues at the incision site provides compliance with flexion of the neck after surgery.



**Figure 2.** The average change in visual analog scale (VAS) pain score and pain disability index (PDI) after initiation of occipital electrical stimulation. Note a significant improvement in pain scores and functional capacity measured as PDI 3 mo after implantation.

There is an obvious need for well designed long-term studies in which the efficacy of electrical stimulation will be compared with other treatments used for intractable occipital neuralgia.

## References

1. Loeser JD. Cranial neuralgias. In: Loeser JD, ed. *Bonica's management of pain*. 3rd ed. Philadelphia: Lippincott, Williams & Wilkins, 2001:855-66.
2. Dubuisson D. Treatment of occipital neuralgia by partial posterior rhizotomy at C1-3. *J Neurosurg* 1995;82:581-6.
3. Stechison MT, Mullin BB. Surgical treatment of greater occipital neuralgia: an appraisal of strategies. *Acta Neurochir* 1994;131:236-40.
4. Magnusson T, Ragnarsson T, Bjornsson A. Occipital nerve release in patients with whiplash trauma and occipital neuralgia. *Headache* 1996;36:32-6.
5. Weiner RL, Reed KL. Peripheral neurostimulation for control of intractable occipital neuralgia. *Neuromodulation* 1999;2:217-21.
6. Lou L. Uncommon areas of electrical stimulation for pain relief. *Curr Rev Pain* 2000;4:407-12.
7. Hammer M, Doyles DM. Perineuromal stimulation in the treatment of occipital neuralgia: a case study. *Neuromodulation* 2001;4:47-51.
8. Pollard CA. Preliminary validity study of the pain disability index. *Percept Mot Skills* 1984;59:974.