

## LETTER TO THE EDITOR

# Neuromodulation of the Great Auricular Nerve: A Case Report

## To the Editor:

Among headache disorders, migraine headache is the most common headache disorder prompting patients to present to primary care physicians, neurologists, and pain physicians. Although the underlying cause of migraine headache is unknown, there is growing evidence that the upper cervical nerves may play a significant role in migraine and cluster headache and that these nerves may be important therapeutic targets for these and other primary headache disorders (1).

Exciting basic science research has uncovered an important connection between the trigeminocervical complex and the manifestation of primary headache syndromes, such as migraine and cluster headaches. For instance, direct coupling between meningeal afferents and cervical afferents in the spinal dorsal horn has been recently described in detail. Moreover, mapping of the trigeminocervical complex in cats revealed that nociceptive afferents reside in the caudal region of the trigeminal nucleus caudalis and extend into the dorsal horns of the C1 and C2 cervical segments without extending significantly to the C3 level. These neurons were easily accessible and could be activated by both electrical and mechanical stimuli (2). As a result, it is plausible that the trigeminocervical complex may serve as an important therapeutic target for the treatment of primary headache syndromes. Currently, a commonly employed treatment for primary headache disorders involves occipital nerve injection with a local anesthetic and corticosteroids.

The great auricular nerve (GAN) is a purely sensory nerve and is the largest of the ascending branches of superficial branches of the cervical plexus. The GAN arises from the second and third cervical nerves (C2 and C3), winds around the posterior border of the sternocleidomastoid, and after perforating the deep fascia, ascends upon that muscle beneath the platysma to the parotid gland, where it divides into an anterior and a posterior branch. The branches are distributed to the skin of the face over the parotid gland and the skin over the mastoid process, extending to the back of the auricle. Great auricular branches communicate with the lesser occipital nerve, the auricular branch of the vagus nerve, and the posterior auricular branch of the facial nerve (3).

Regardless of the length of the sternocleidomastoid, the GAN at its most superficial location was found to be at a consistent ratio of one-third the distance from either the mastoid process or the external auditory canal to the clavicular origin of the sternocleidomastoid (4). In addition to the use of surface anatomy (Fig. 1) and bony landmarks for guidance, the external jugular vein can also be used as a landmark for the location of the GAN, as the GAN is

approximately 1 cm superior and lateral to the external jugular vein coursing in a trajectory parallel to the vein (Fig. 2).

Anatomically, the GAN is protected as it courses behind the sternocleidomastoid. Once it emerges onto the anterior surface of the muscle, it resides in a superficial plane, making it accessible for blind injection, yet also vulnerable to traumatic or even iatrogenic injury.

High-definition ultrasonography has revolutionized the visualization of the GAN and other surrounding soft tissues, such as the spinal accessory nerve, greatly facilitating the performance of several targeted interventional pain medicine procedures. For example, a percutaneous GAN peripheral nerve stimulator catheter can be implanted by utilizing ultrasound guidance. Likewise, among posterior cervical triangle structures, ultrasound guidance greatly enhances identification of the spinal accessory nerve, which, due to its relatively long and superficial course in the posterior triangle of the neck, is also vulnerable to iatrogenic injury. An important advantage of utilizing ultrasound guidance for percutaneous nerve stimulator implantation, whether at the GAN or the spinal accessory nerve, is the presence of fewer complications—particularly iatrogenic complications—associated with open surgical permanent implantation of neurostimulation devices.

## CASE PRESENTATION

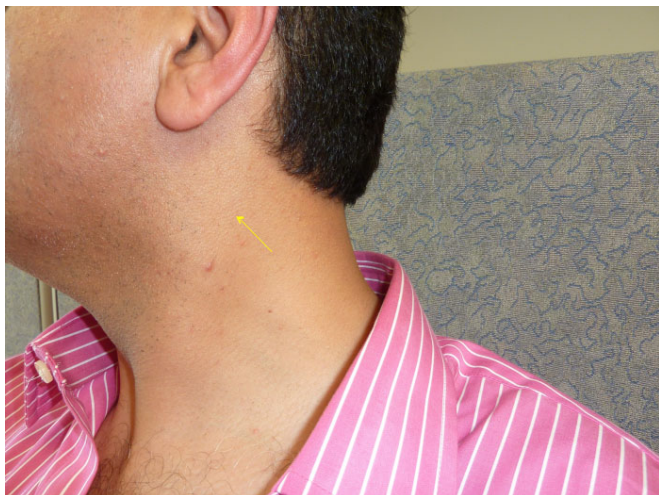A 32-year-old right-handed white female with a body mass index of 38 was referred to our multidisciplinary pain clinic for evaluation of chronic, intractable headache. The patient reported first being diagnosed with migraine headaches in high school, although she recalled having had headaches since childhood. She notes that the headaches were infrequent, about two to three per year, until two years ago when they rapidly became frequent, and then daily. Neither she nor her husband could identify any particular instigating event or lifestyle change that may have precipitated her increased headache frequency.

The patient described her headaches “as a migraine,” with a constant throbbing and stabbing quality. Typically, the headaches

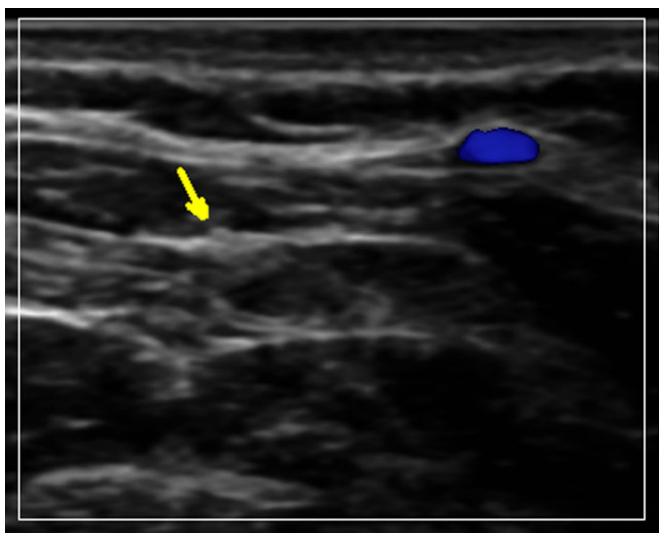
---

Address correspondence to: Foad Elahi, MD, Center of Pain Medicine and Regional Anesthesia, University of Iowa, 200 Hawkins Drive, 5JPP, Iowa City, IA 52242, USA. Email: foad-elahi@uiowa.edu

For more information on author guidelines, an explanation of our peer review process, and conflict of interest informed consent policies, please go to <http://www.wiley.com/bw/submit.asp?ref=1094-7159&site=1>



**Figure 1.** On surface anatomy, GAN emerges onto the anterior surface, approximately at one-third the distance from either the mastoid process or the external auditory canal to the clavicular origin of the sternocleidomastoid (SCM), irrespective of the neck length.



**Figure 2.** Ultrasound picture; cross-section of GAN in approximately 1 cm lateral to superficial jugular vein.

started at the left temple region with two distinct radiating patterns. The first radiated toward the left forehead, to the top of her head, and then posteriorly into the neck and upper back, and the second toward the left jaw and then posteriorly toward her neck and upper back. She denied any pain radiation into her upper extremities but did endorse occasional numbness and tingling in her fingertips during acute headache exacerbations. While her headaches were usually left sided, an increased frequency of right-sided headaches had been recently noticed. Moreover, her headaches were reported as being constant in nature—without a single pain-free day for more than six months—with severe, incapacitating, exacerbations two to three times per week. Pain intensity ranged from a low of 2 to a high of 8 on the 10-point pain numeric rating scale (NRS), whereas her average daily headache was reported as a 4 to 6 on the NRS.

Several associated symptoms were reported by the patient, the most common being photophobia, phonophobia, nausea, and

vomiting, although vomiting was only associated with her most severe, incapacitating headaches. Less commonly occurring associated symptoms included neck tightness, leg and hand twitching, visual hallucinations, and memory difficulties described as “lost moments of time”. Noted exacerbating factors were bright lights, loud sounds, and activities that required sustained mental concentration, such as multitasking. The sole consistent relieving factor reported was sleep.

The patient’s headaches were extremely disabling, as their unpredictable and severely incapacitating nature prohibited the patient from participating in gainful employment for more than two years. Needless to say, the patient’s quality of life suffered greatly. Her past medical history was significant for autoimmune hemolytic anemia, for which she was followed regularly in our internal medicine clinic; no history of seizure disorder or head trauma was reported. Her social history was significant for being married and drinking a glass of wine weekly; she denied tobacco or recreational drug use.

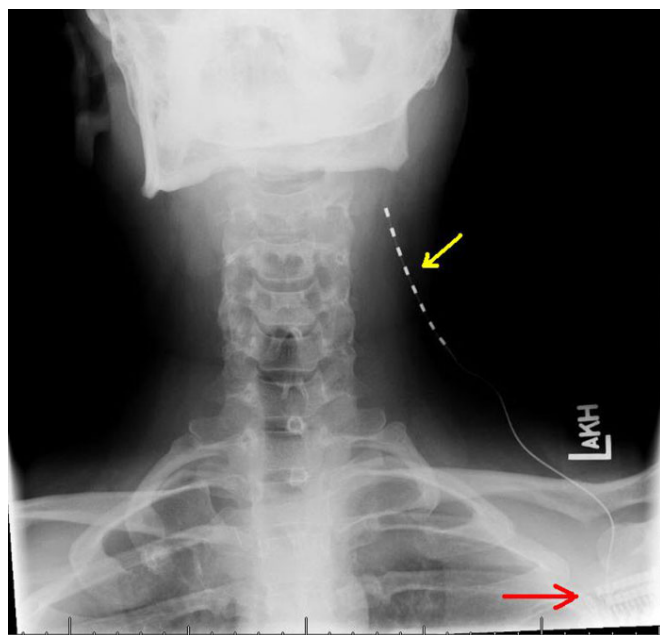
An extensive workup was carried out under the direction of the patient’s primary neurologist. Due to a concern for seizures, the patient was hospitalized to undergo a thorough seizure and general neurologic evaluation. During this hospitalization, neuropsychiatric testing was performed, which reported that she had anxiety. As the patient also voiced occasional complaints of palpitations, the cardiology service was consulted as well. After a thorough cardiac workup that was negative for arrhythmias or other cardiac pathology, her occasional palpitations were attributed to her anxiety. A brain magnetic resonance imaging (MRI) was reassuring, as no space occupying lesions or acute intracranial findings were reported.

Additional testing performed by her primary neurologist in the past included a cervical MRI, a three-day video electroencephalogram (EEG), and two prior sleep studies. The MRI was negative; the EEG did not capture any identifiable seizure activity, and the sleep studies were both found to be normal.

The patient’s primary neurologist initiated a conservative, multimodal treatment plan. This plan consisted of trialing the following: nonsteroidal anti-inflammatory agents, carbamazepine, and valproic acid for headache prophylaxis; Imitrex (GlaxoSmithKline plc, Philadelphia, PA) injections and tablets as headache abortive agents; as well as physical therapy, biofeedback, hypnotherapy, and cognitive behavioral therapy. Despite this multimodal approach, her quality of life continued to suffer, as these attempts failed to achieve any short- or long-term pain alleviation.

Secondary to persistent intractable pain, the patient was referred to our pain clinic for further evaluation. After obtaining a detailed history, performing a thorough physical examination—which was without any focal neurologic findings—and reviewing all prior imaging studies and tests performed, the findings were strongly suggestive of a diagnosis of primary, migraine headache. We initiated the patient on propranolol SR 160 mg daily and amitriptyline 25 mg at bedtime for migraine prophylaxis, both of which she was able to tolerate without any reported intolerable side effects, yet were of minimal prophylactic efficacy. Additionally, a short course of glucocorticoids was trialed; however, this also provided minimal pain alleviation.

As her headaches were resistant to all oral medications trialed, we decided to turn our therapeutic focus toward potential interventional injections and procedures. At first we performed two courses of botulinum toxin injections without any resultant therapeutic benefit. We then trialed several different nerve blocks, including greater occipital, lesser occipital, supraorbital, and infraorbital injections. Of these, she reported a short course of pain relief only after the occipital nerve blocks.



**Figure 3.** GAN stimulator lead. Final lead position (yellow arrow), pulse generator location (red arrow).

As the patient's severe headaches not only persisted unabated but also worsened—with her reporting more frequent, intense headaches of 8 out of 10—we proposed trialing a GAN block, to which the patient agreed. Under ultrasound guidance, a left-sided GAN block was performed using an injectate of 3 mL of 0.25% bupivacaine. The patient reported immediate pain relief with a total absence of headache, lasting eight hours. Subsequent repeat GAN blocks with the same positive analgesic response on two other occasions confirmed the first response as valid and not due to placebo. In light of the positive GAN block results, we discussed GAN neurostimulator implantation as a potential option for long-term treatment. The patient agreed to undergo permanent GAN stimulator implantation, and the procedure was done utilizing ultrasound guidance and percutaneous leads (Fig. 3). The procedure was tolerated well by the patient without any complications.

At six-month follow-up postpermanent neurostimulator implantation, the patient reported significant, sustained pain alleviation, with daily baseline pain scores averaging one to two on the NRS scale. Furthermore, she was able to decrease her amount of analgesic medication use. In fact, she also reported not requiring any abortive medication for the past three months, as she had not experienced any further headache episodes. Overall, she was extremely satisfied with the positive results.

## DISCUSSION

Headaches are often difficult to treat, particularly because significant symptomatic overlap among primary headache syndromes makes establishment of an accurate diagnosis challenging. As such, an integrated, interdisciplinary approach is of the highest priority for this patient group. With the implementation of multidisciplinary and multimodal approaches, only a small minority of chronic migraine patients remain refractory to treatment. This select group of migraine patients may potentially be appropriate candidates for electrical neuromodulation treatment.

For more than a decade, the use of neuromodulation for occipital neuralgia, as well as other primary headache syndromes, has become a widespread successful therapy (5). Although fewer case reports discuss neuromodulation for patients with cervicogenic and C2-mediated headaches, evidence in support of this use also exists (6,7). The most commonly accepted mechanism of action for this treatment is believed to involve stimulation of the distal branches of C2 and C3 that convergence with the trigeminal system, possibly inhibiting central nociceptive processing (8). As favorable pain alleviation results have been seen with neurostimulation of the occipital nerve, we considered neurostimulation of the GAN—which is also composed of branches of C2 and C3—to see if similar pain alleviation effects would be produced. In our case report, we were able to demonstrate excellent pain relief not only on the ipsilateral but also on the contralateral side. This advantageous finding correlates with the underlying convergent synaptic connections between the trigeminocervical neurons and both ipsilateral and contralateral afferents (9). Collectively, these findings lend support for the convergent nature of trigeminocervical synaptic input while also demonstrating that neurostimulation actively inhibits nociceptive input both ipsilateral and contralateral.

To the best of our knowledge, there have been no publications to date concerning the application of peripheral nerve stimulation over the GAN. This unique application of neuromodulation is an adaptation of two currently accepted chronic headache treatments—greater occipital nerve blocks and occipital nerve neuromodulation—and its efficacy is believed to be derived from the same mechanism of action. On the whole, neuromodulation harbors several inherent advantageous qualities: It is nondestructive, minimally invasive, and usually fully reversible.

Determining which chronic headache patients are appropriate candidates for neuromodulation poses a unique challenge. Ideal candidates for GAN neuromodulation are those patients that fall under the category of medically “intractable headache,” defined as headache that is uncontrollable, unmanageable, and/or refractory to multimodal treatment. Satisfactory pain relief after a GAN block serves an important prognostic role in identifying appropriate GAN neuromodulation candidates. Patients with a diagnosis of chronic daily headache are often not appropriate candidates for GAN neuromodulation and deserve a more thorough workup for a more specific headache classification. A thorough workup—consisting of a complete history and physical examination, brain imaging studies, and an indomethacin test—is crucial to rule out other diagnoses and to correctly classify each headache presentation. Establishment of an International Headache Society diagnosis is desirable before consideration of any device-based therapy.

The positive outcome chronicled in our case presentation suggests that peripheral nerve stimulation of the GAN should be considered as a potentially viable and safe therapeutic option for primary, refractory headaches. From our experience, we recommend ultrasound guidance be used to perform GAN neurostimulator, to decrease the surgical complication risk of GAN damage, and also to avoid accessory nerve injury.

In recent years, neuromodulation has experienced a renaissance as a treatment option for a variety of chronic pain conditions. GAN neuromodulation offers a unique opportunity to better understand and reduce the disability of a proportion of patients with medically intractable, primary headache disorders. This case report potentially opens yet another treatment option in the armamentarium of interventional pain medicine practitioners against chronic, primary headache.

Foad Elahi, MD\*; Chandan Reddy, MD†; Anke Bellinger, MD\*;  
Nicholas Manolitsis, MD‡

\*Center of Pain Medicine and Regional Anesthesia,  
University of Iowa, Iowa City, IA, USA;

†Department of Neurological Surgery,  
University of Iowa, Iowa City, IA, USA; and

‡Physical Medicine and Rehabilitation,  
Mercy Medical Center, Des Moines, IA, USA

### Acknowledgment

The authors on this article deny any conflict of interests.

### Authorship Statement

All of the authors contributed substantially in writing and data collection equally.

### REFERENCES

1. Ashkenazi A, Blumenfeld A, Napchan U et al. Peripheral nerve blocks and trigger point injections in headache management—a systematic review and suggestions for future research. *Headache* 2010;50:943–952.
2. Kaube H, Hoskin KL, Goadsby PJ. Activation of the trigeminovascular system by mechanical distension of the superior sagittal sinus in the cat. *Cephalalgia* 1992;12:133–136.
3. Clemente C. *Gray's anatomy of the human body*, 30th ed. Philadelphia: Lea & Febiger, 2010:1396. ISBN-13: 9781435114937.
4. Lefkowitz T, Hazani R, Chowdhry S, Elston J, Yaremchuk MJ, Wilhelmi BJ. Anatomical landmarks to avoid injury to the great auricular nerve during rhytidectomy. *Aesthet Surg J* 2013;33:19–23.
5. Saper JR, Dodick DW, Silberstein SD, McCarville S, Sun M, Goadsby PJ. Occipital nerve stimulation for the treatment of intractable chronic migraine headache: ONSTIM feasibility study. *Cephalalgia* 2011;31:271–285.
6. Rodrigo-Royo M, Azcona JM, Quero J, Lorente MC, Acin P, Azcona J. Peripheral neurostimulation in the management of cervicogenic headache: four case reports. *Neuromodulation* 2005;8:241–248.
7. Melvin EA, Jordan FR, Weiner RL, Prim D. Using peripheral stimulation to reduce pain of C2-mediated occipital headaches: a preliminary report. *Pain Physician* 2007;27:153–157.
8. Goadsby JP, Bartsch T, Dodick D. Occipital nerve stimulation for headache: mechanisms and efficacy. *Headache* 2008;48:313–318.
9. Bartsch T, Goadsby PJ. Stimulation of the greater occipital nerve induces increased central excitability of dura afferent input. *Brain* 2002;125:1496–1509.

**Keywords:** Great auricular nerve, great auricular neuralgia, headache, neuromodulation, neurostimulation